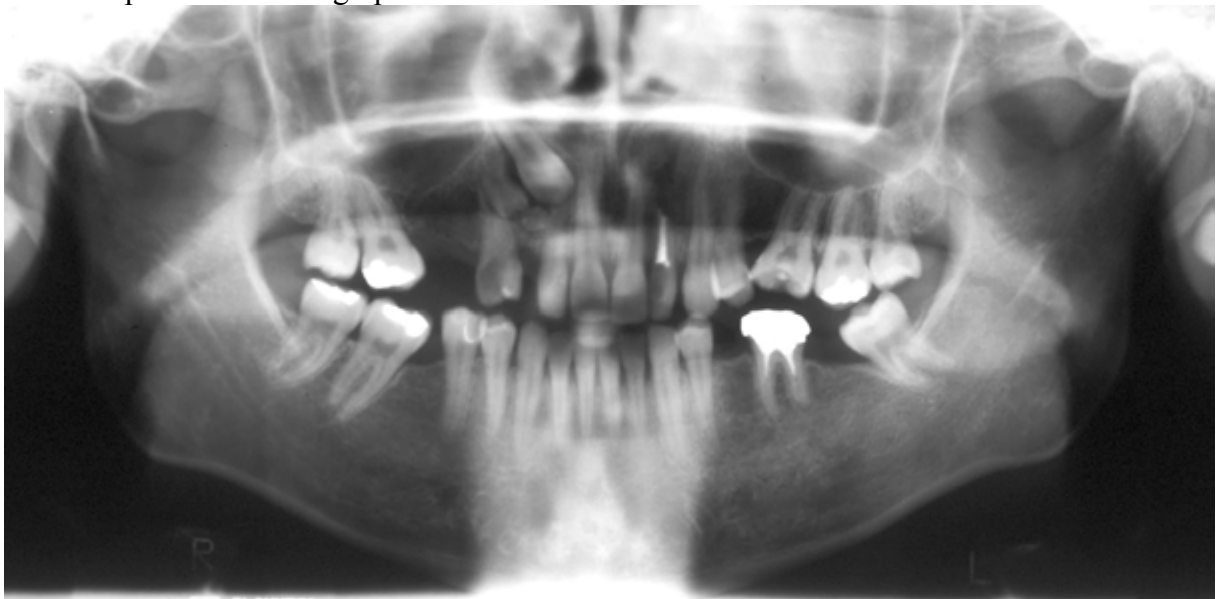

In the first case I would like to show you auto transplantation, in the second case replantation and in the third case something what I tried to do and I think it was successful.

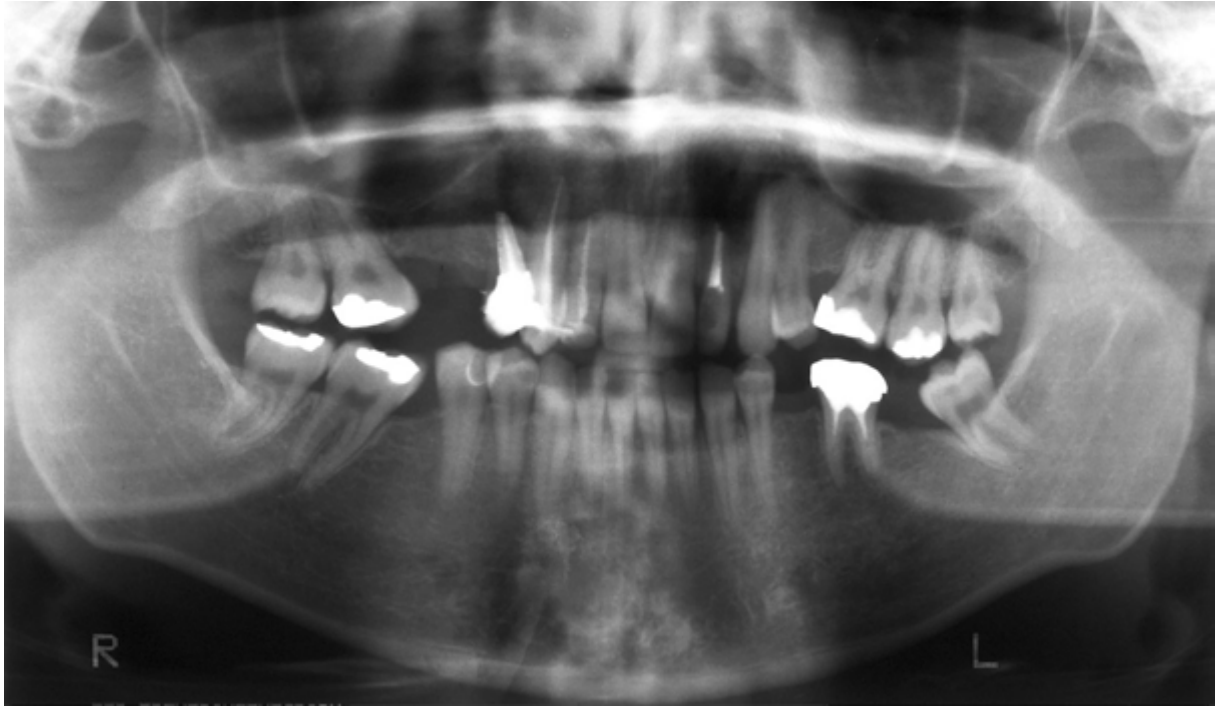
I.

In the first case the patient was born on 8 March 1973
She came to my office on 30 September 1996. I made some x-ray pictures.

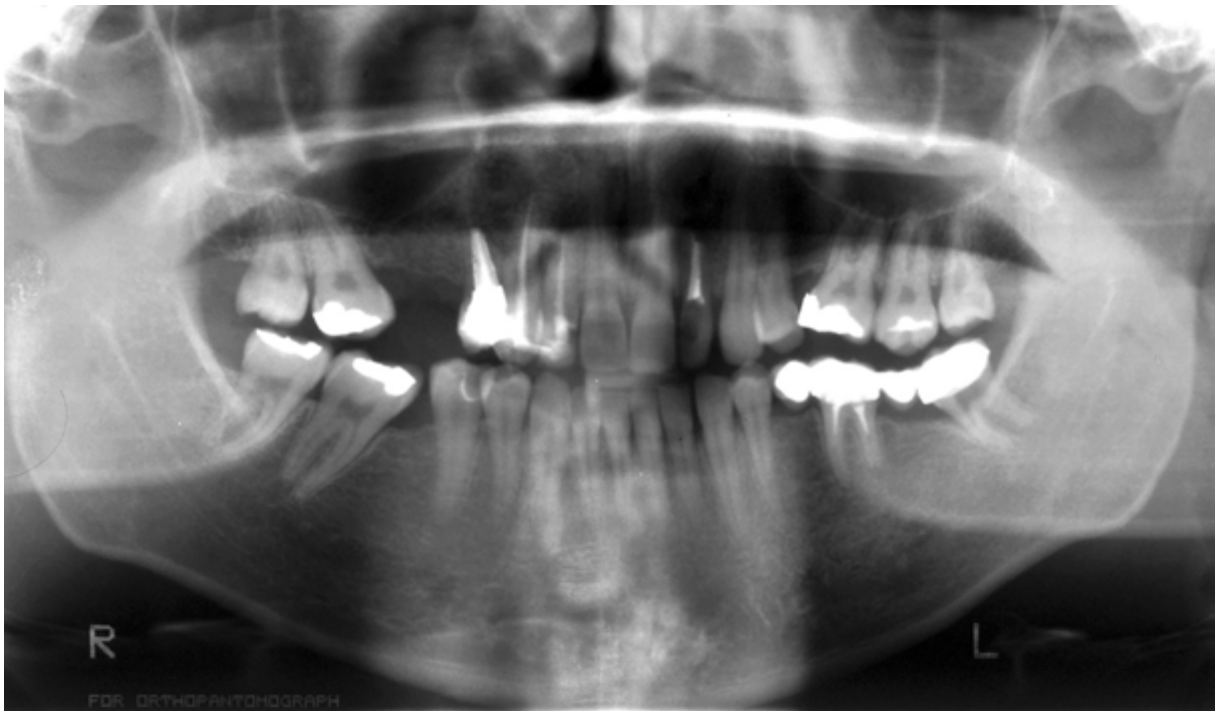12.09.96 panoramic radiograph



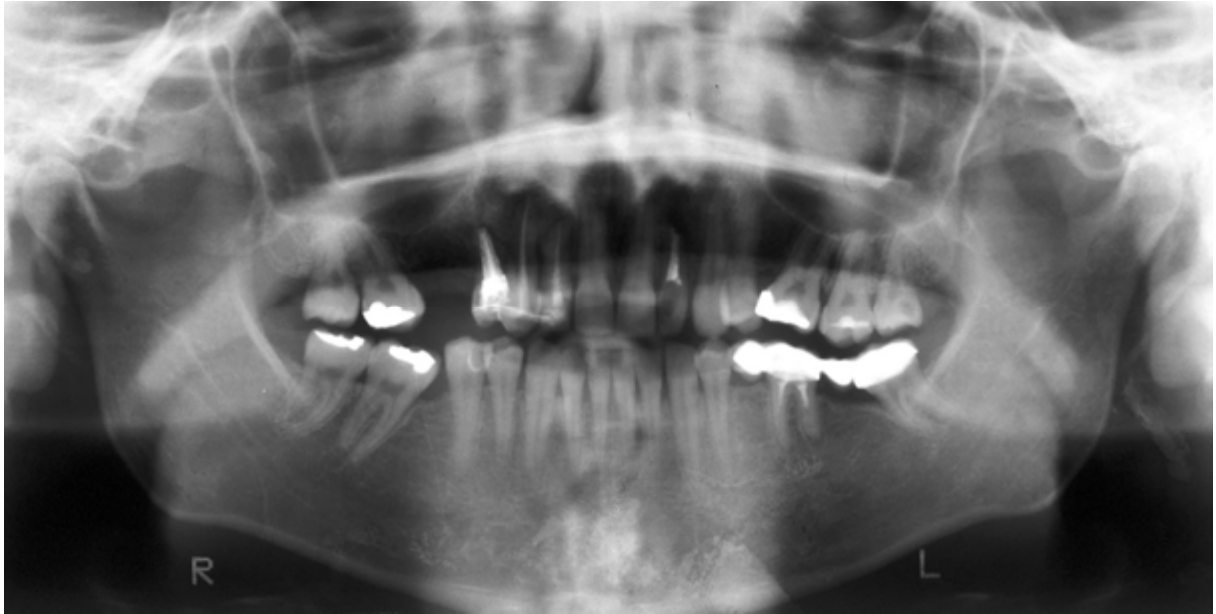
As you can see, she had a big retention cyst on tooth 13. Also tooth 14 was involved.
I decided to put tooth 13 to the right place. During the operation I filled root canal of tooth 13 in the hand and tooth 14 in the mouth. I made exkohleation of the cyst and filled up the hole with bone graft (bio-os) a covered it with absorbable membrane (gore). I sewed the wound and then fixed the three teeth together with a stable block.
You can see the result on x-ray pictures and on the slide.



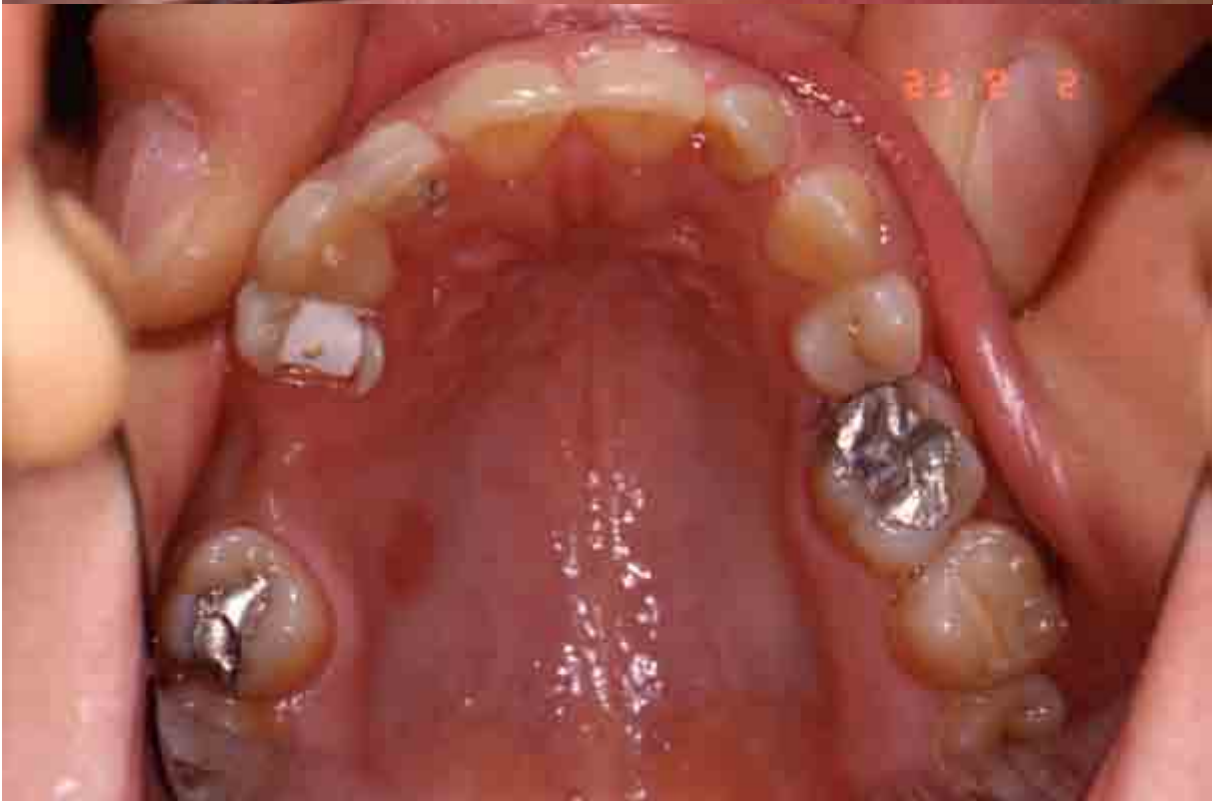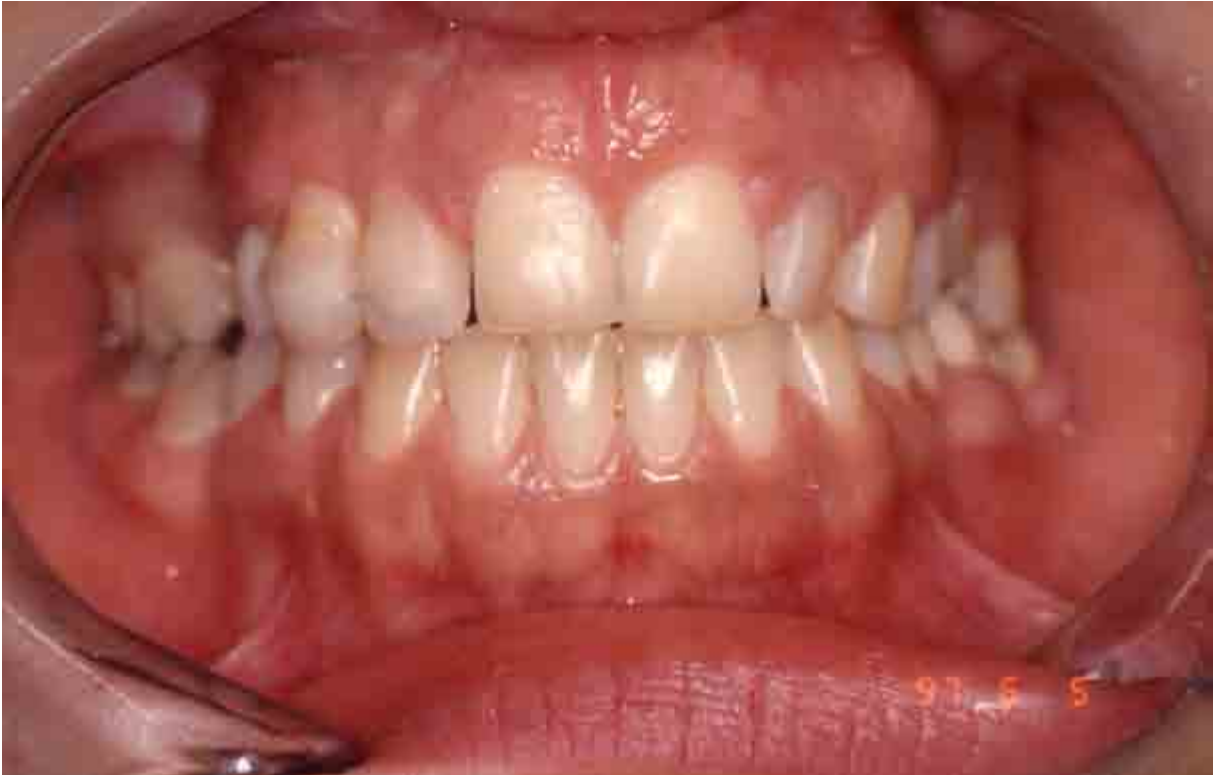21.10.96 panoramic radiograph

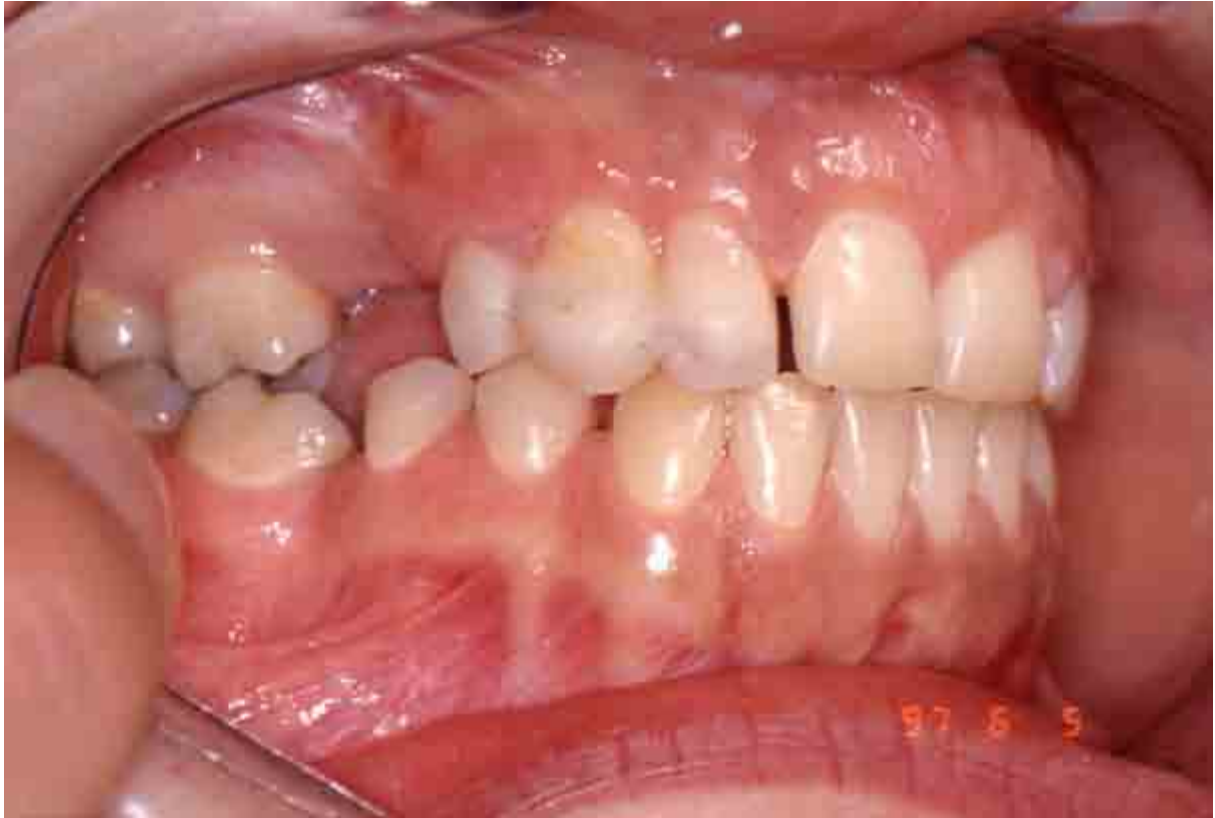

08.01.97 panoramic radiograph



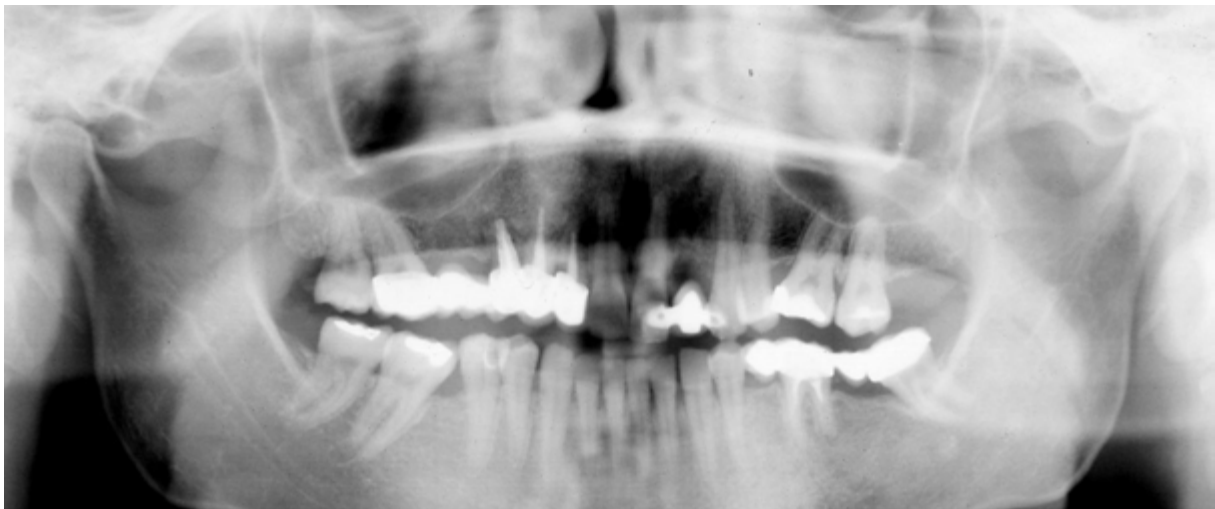
12.05.97 panoramic radiograph





Pictures before bridge

After eight months I made a metal ceramic bridge on teeth 17,14, 13, 12.



24.10.98 panoramic radiograph

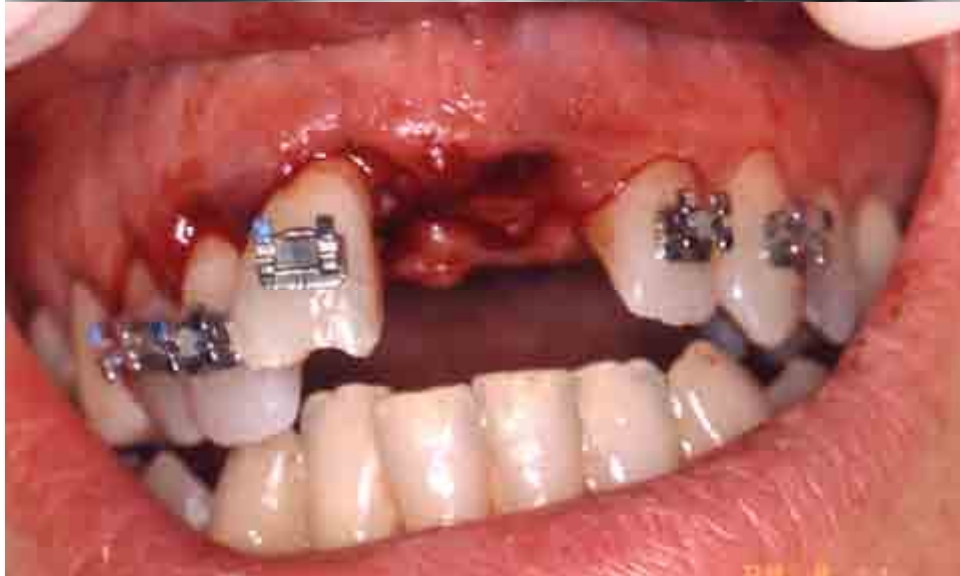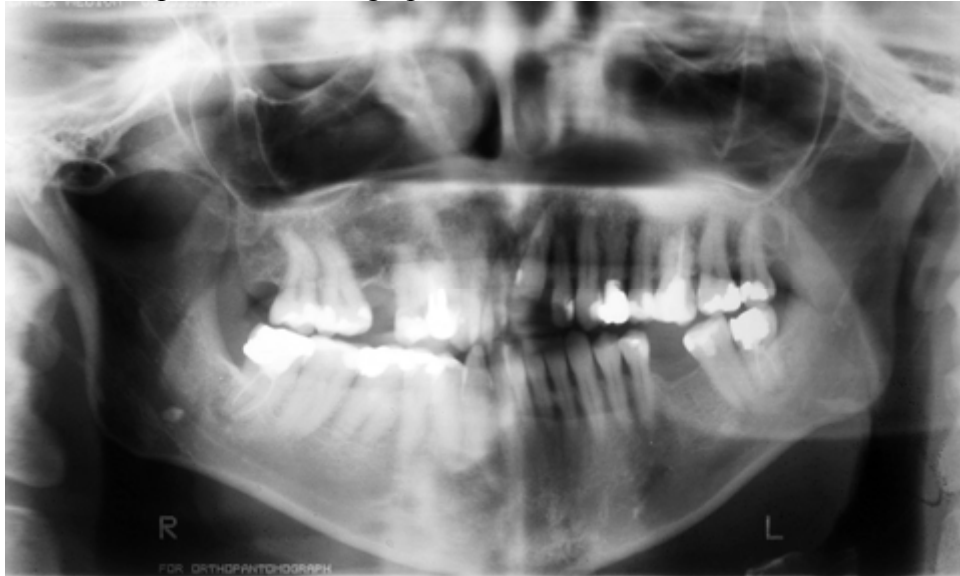The last time I saw her was in year 2001 and there were no changes or other problems with the teeth on the right upper side.

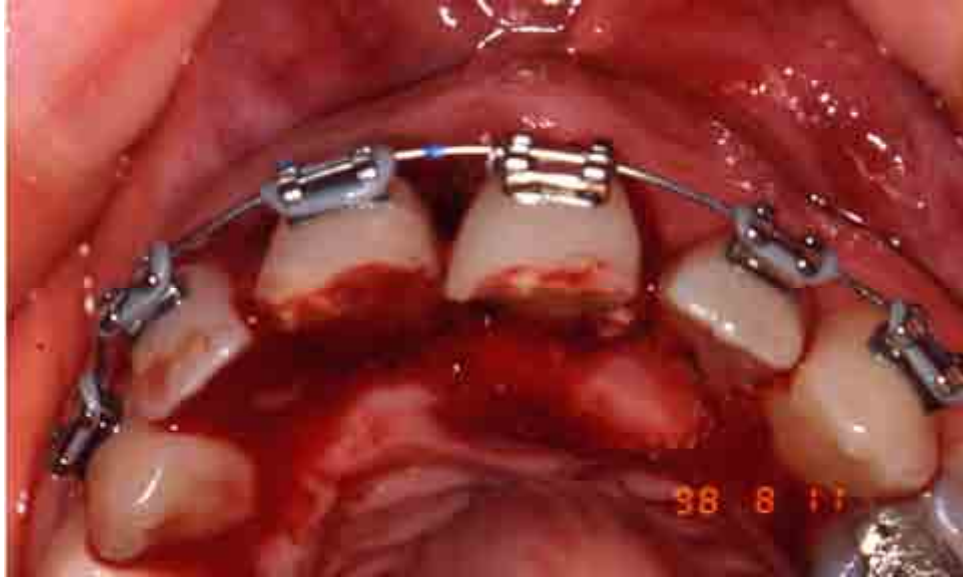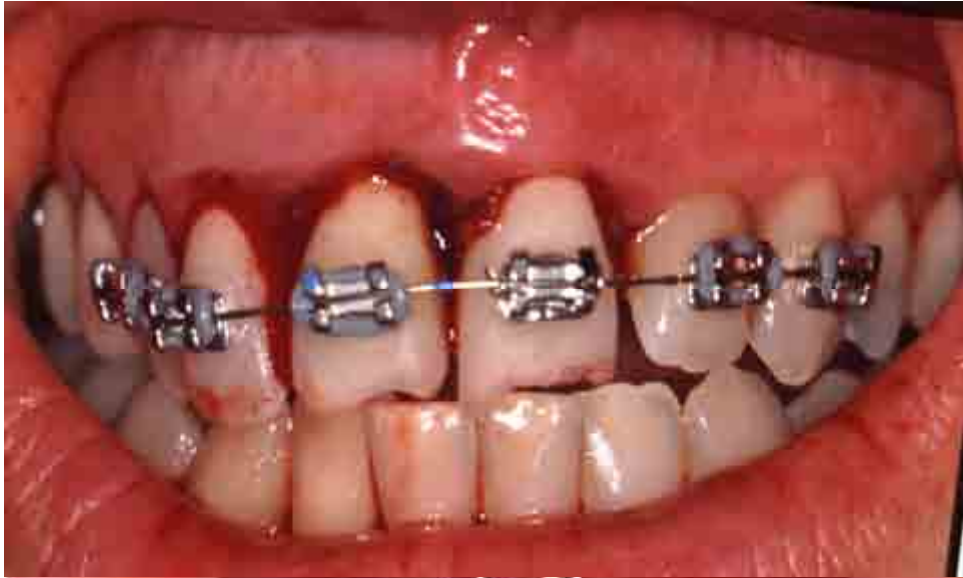II.

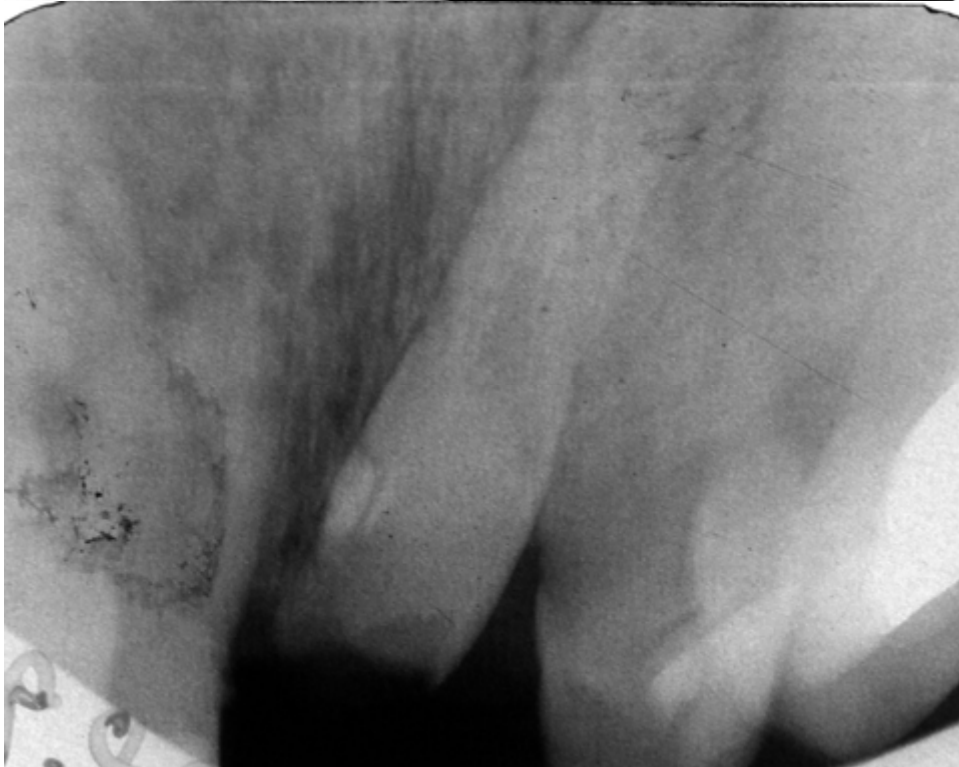
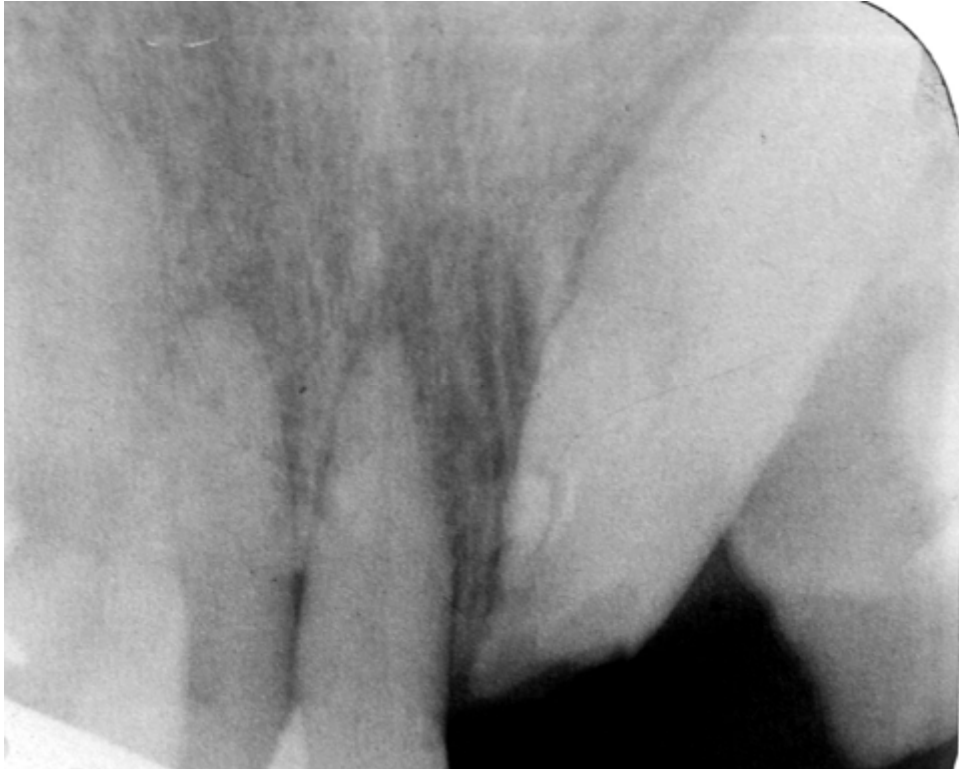The second case was born on 31 March 1956

She had a car accident on 10 August 1998. Her front teeth were injured. You can see on the slide and on x-ray picture that tooth 21 was completely intruded in the bone, teeth 12, 11, 22 were compressed in the bone.

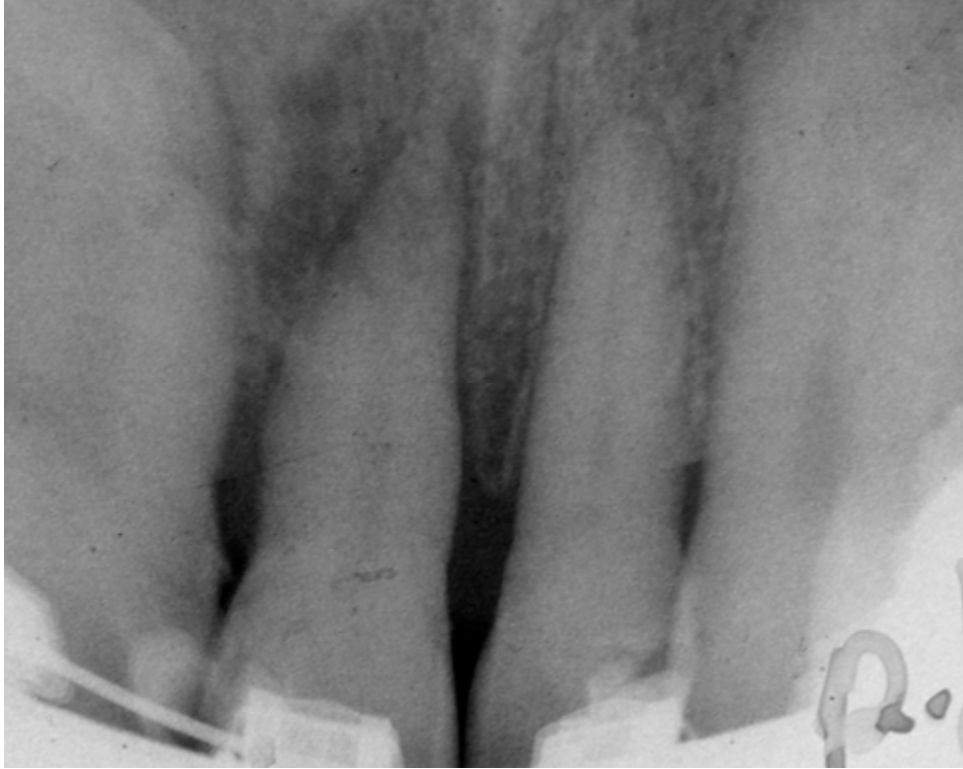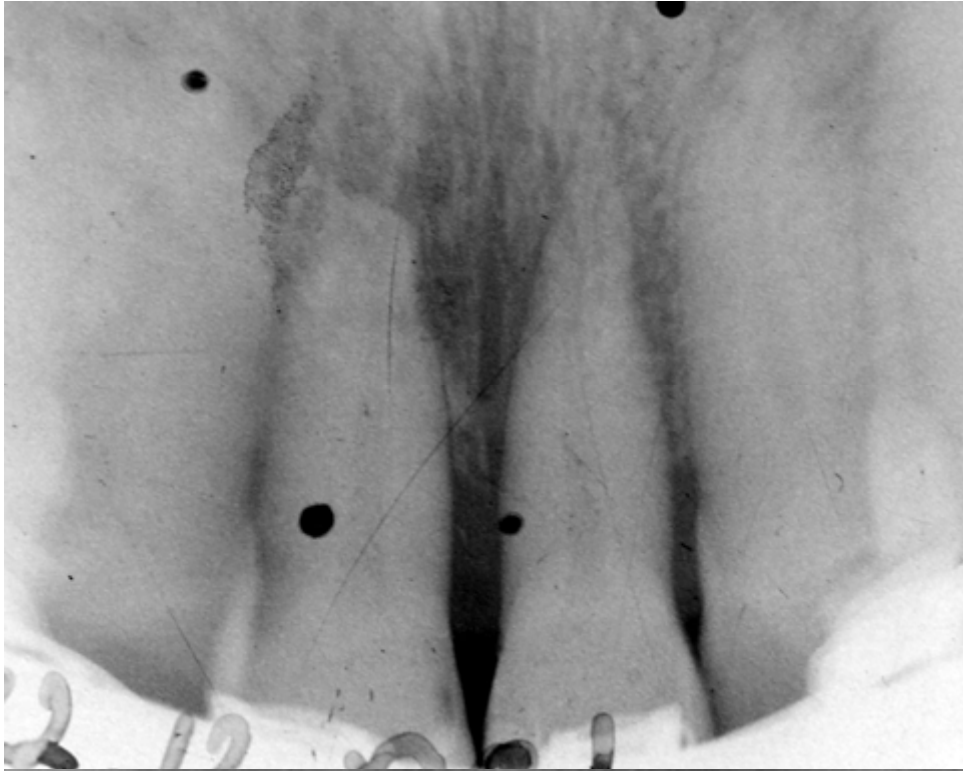
10.08.9898 panoramic radiograph



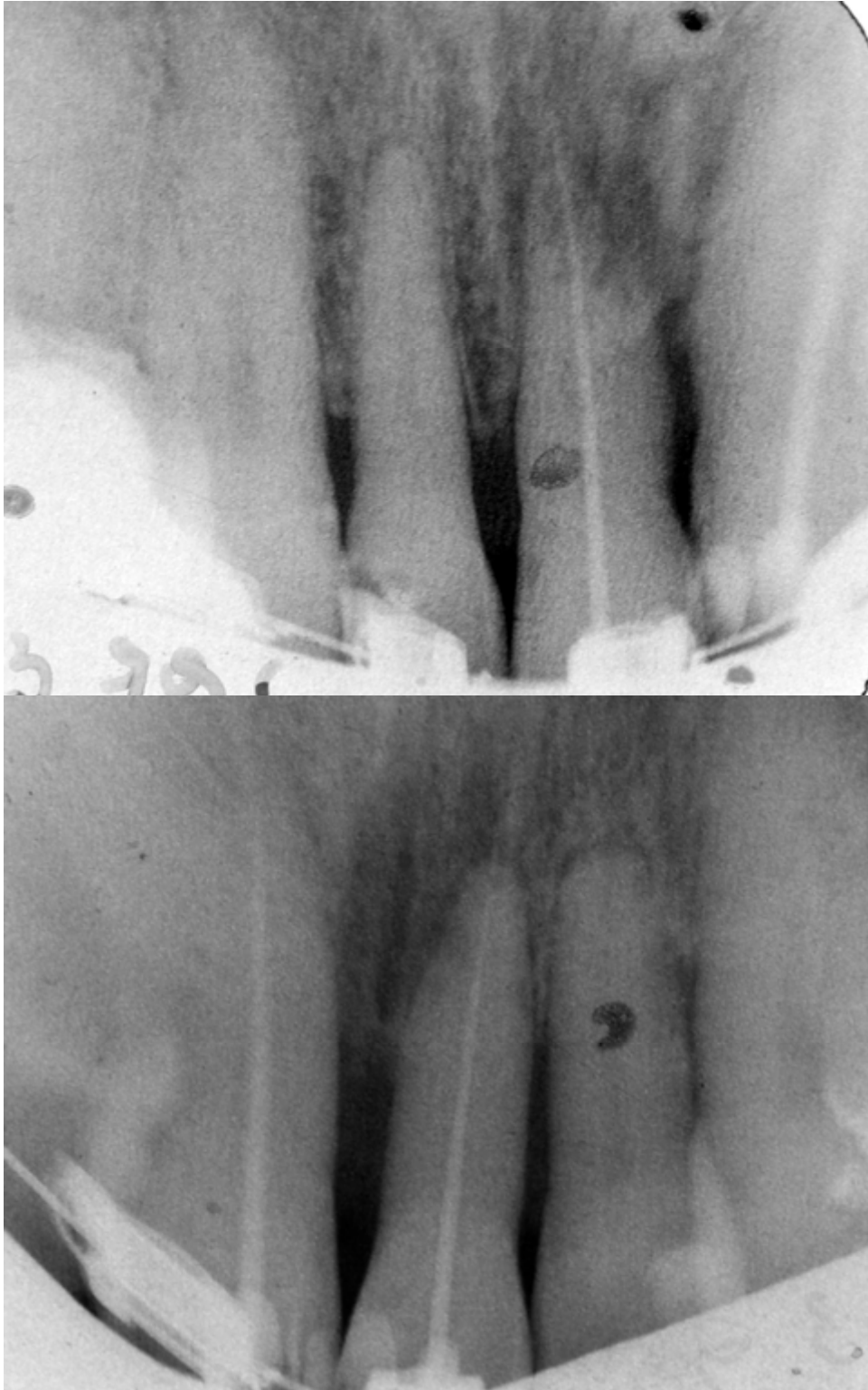




The results of the vitality test were negative on all four teeth. I decided to reposition tooth 21, made fixation with placing brackets and wire from 15 to 25 and at the same time to do some repositioning of the teeth. In next step I filled all root canals on teeth 12, 11, 21, 22.



12.12.98 local roentgenogram



30.03.99 local roentgenogram

You can see some results on the pictures. I don't have the final result in my documentation. I linked the front teeth together with a stable block. The last time I saw her was in year 2000 and there were no changes.