
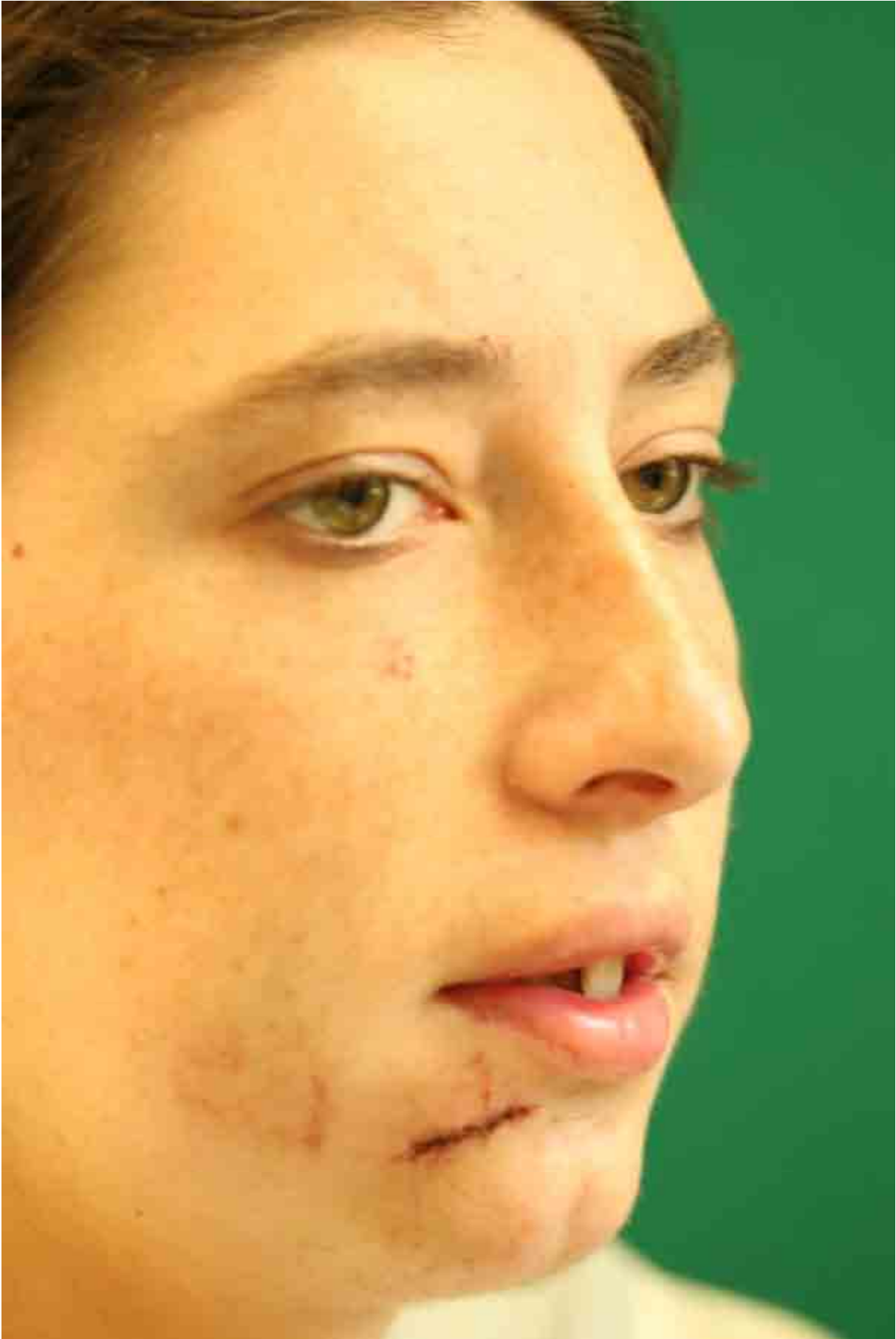


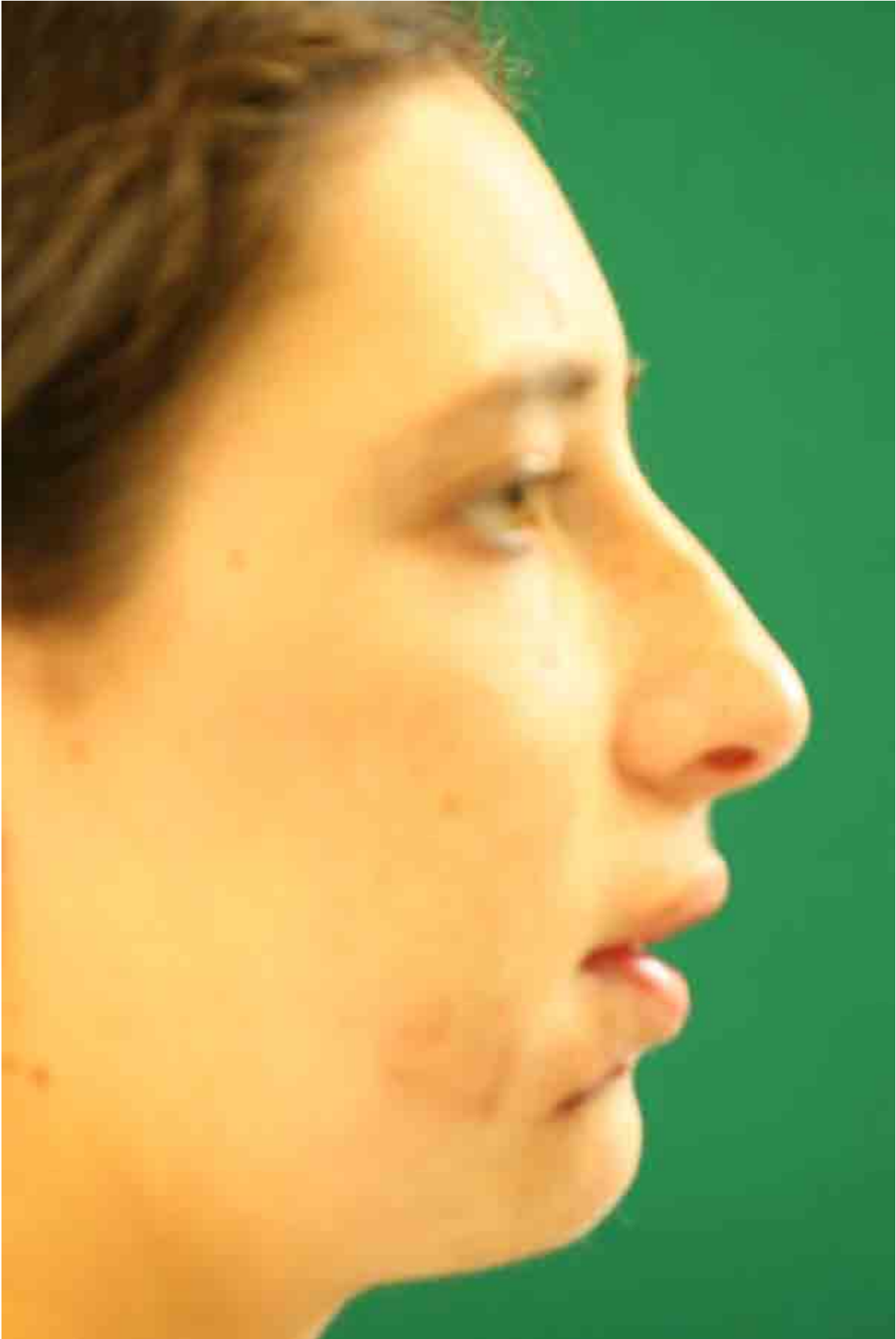
III.

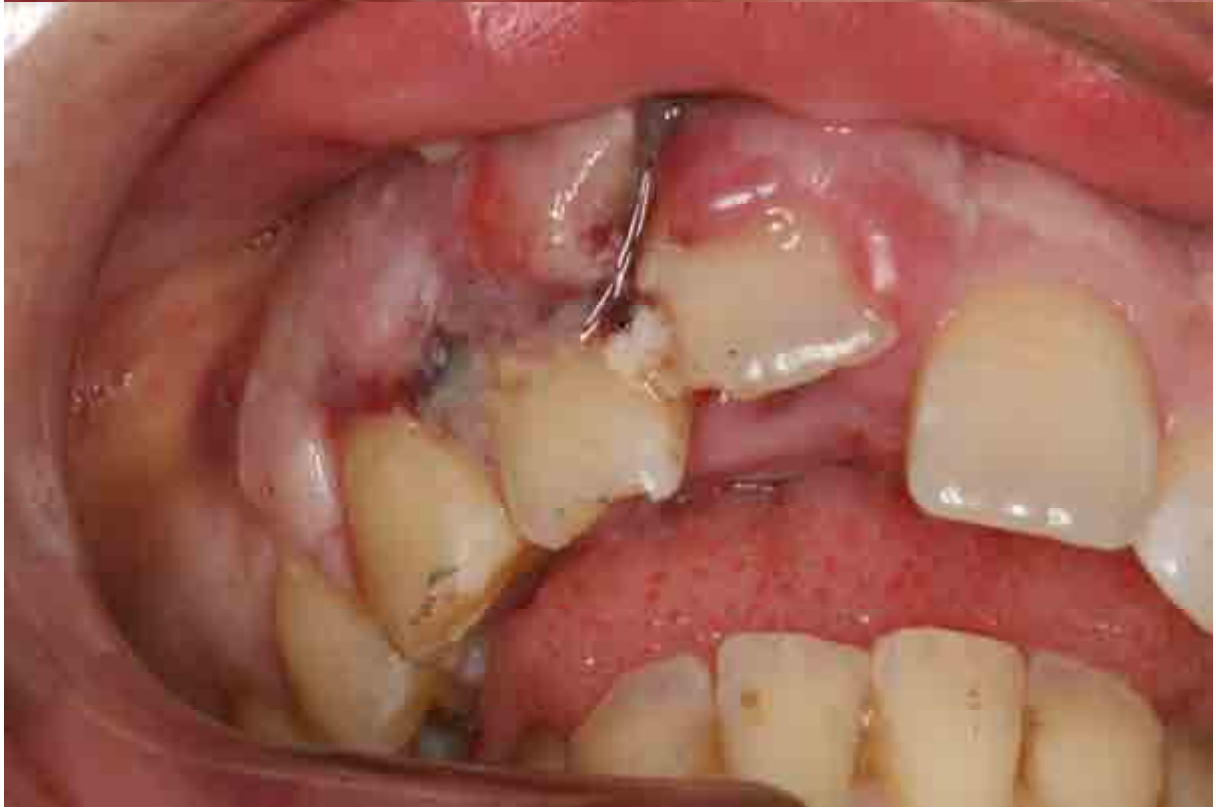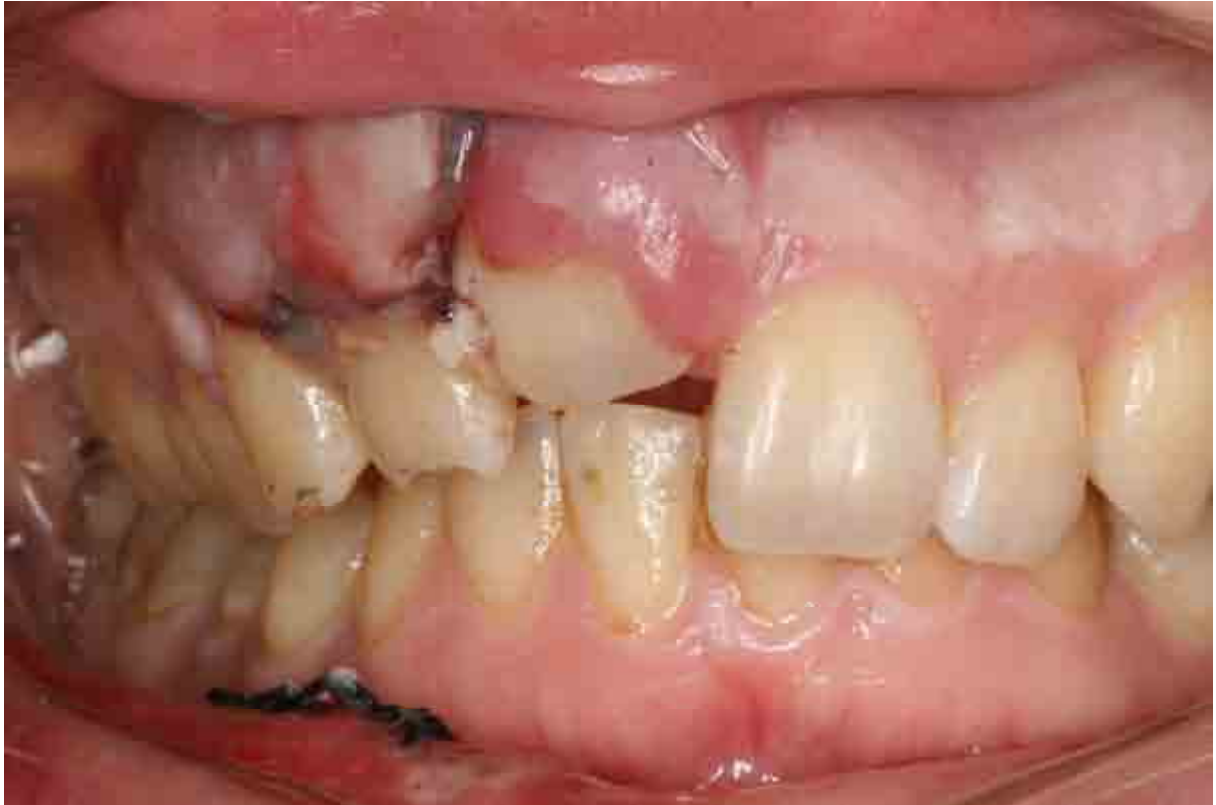Here she comes. My friend's daughter. She also had a car accident. She was born on 8 June 1983. She came on 19 May 2007. You can see her condition on the pictures.

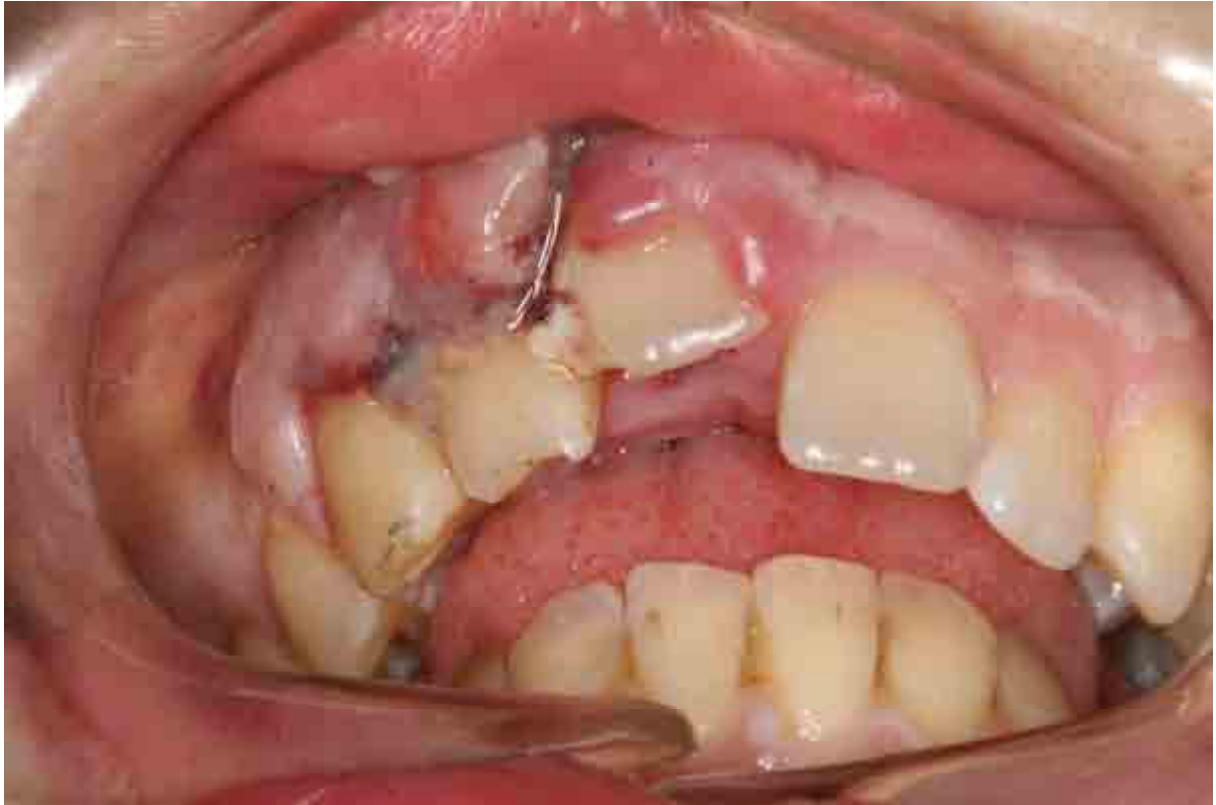




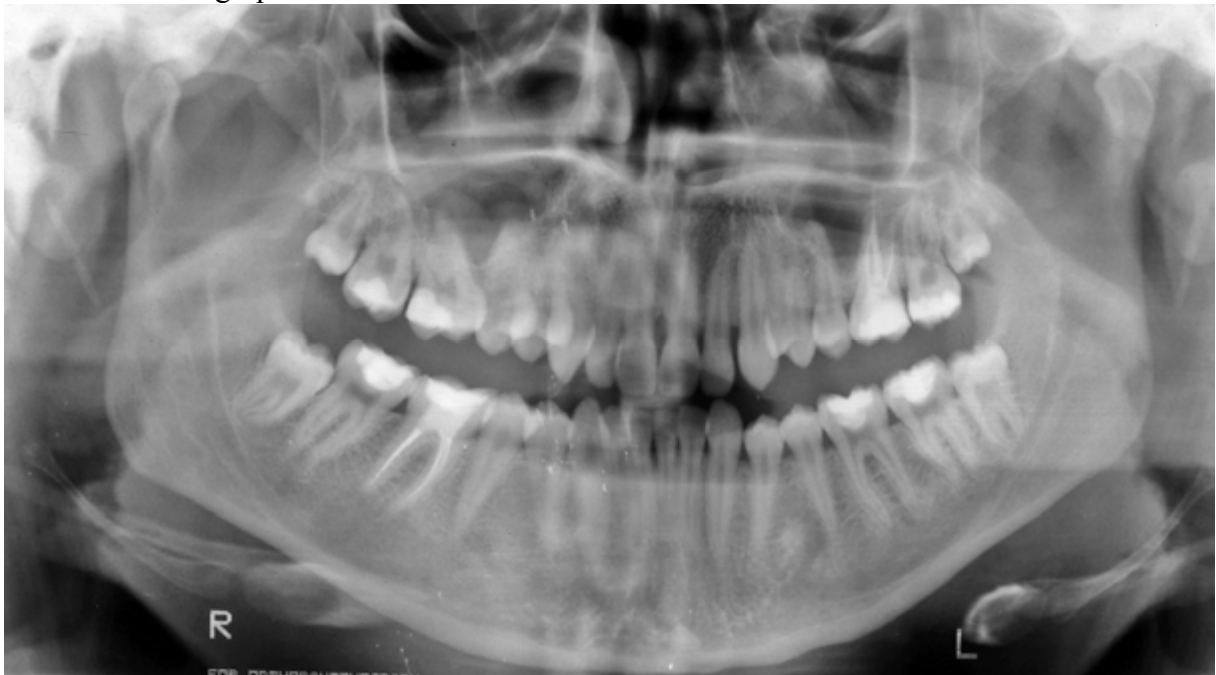


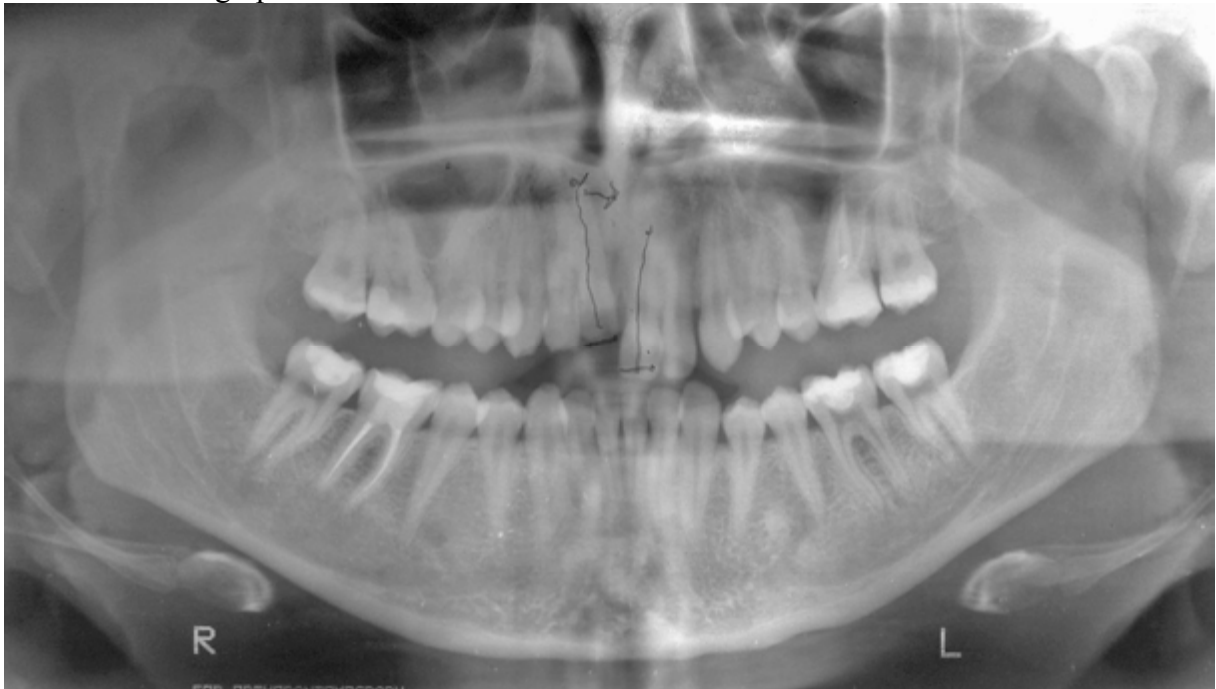




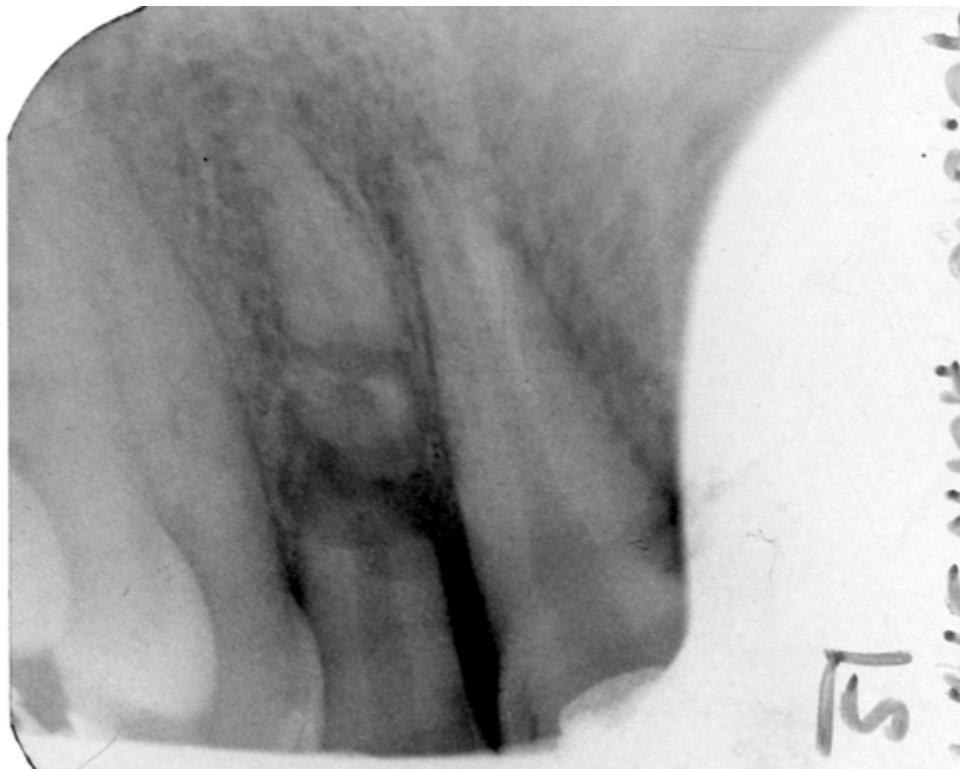
Panoramic radiograph before accident 31.05.2005



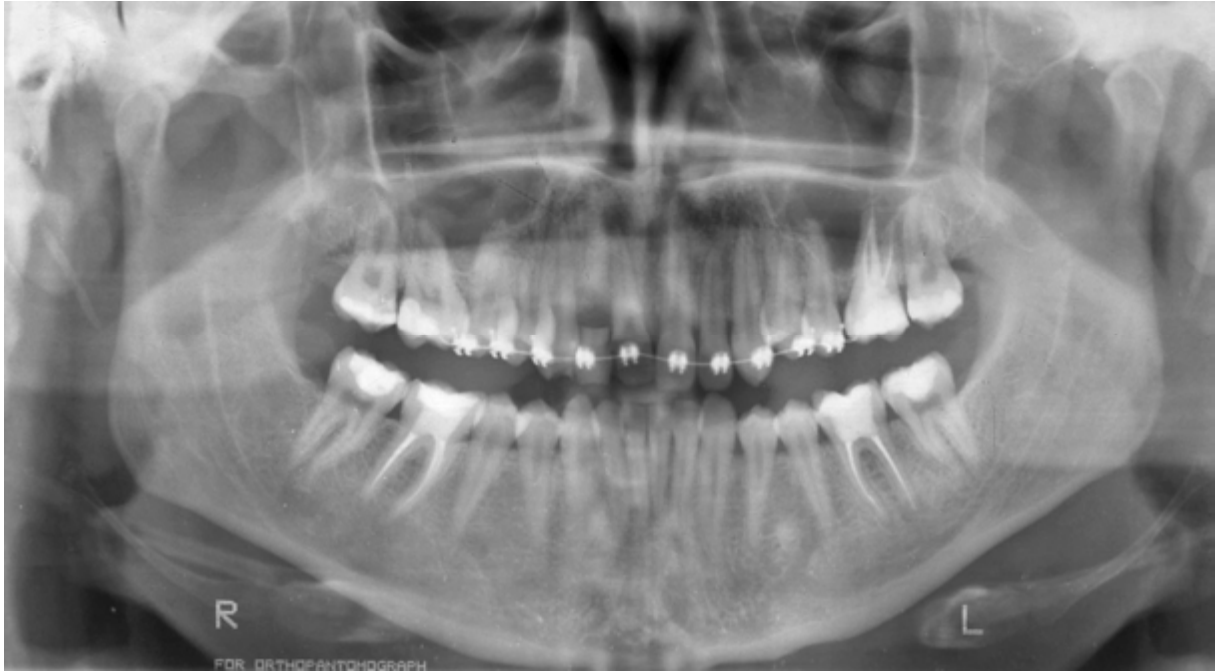Panoramic radiograph after accident 29.05.2007



I decided to put brackets and wire from 15 to 25. But I didn't decide to reposition teeth 12 and 11 but to pull them out of the bone orthodontic. Did I succeed?

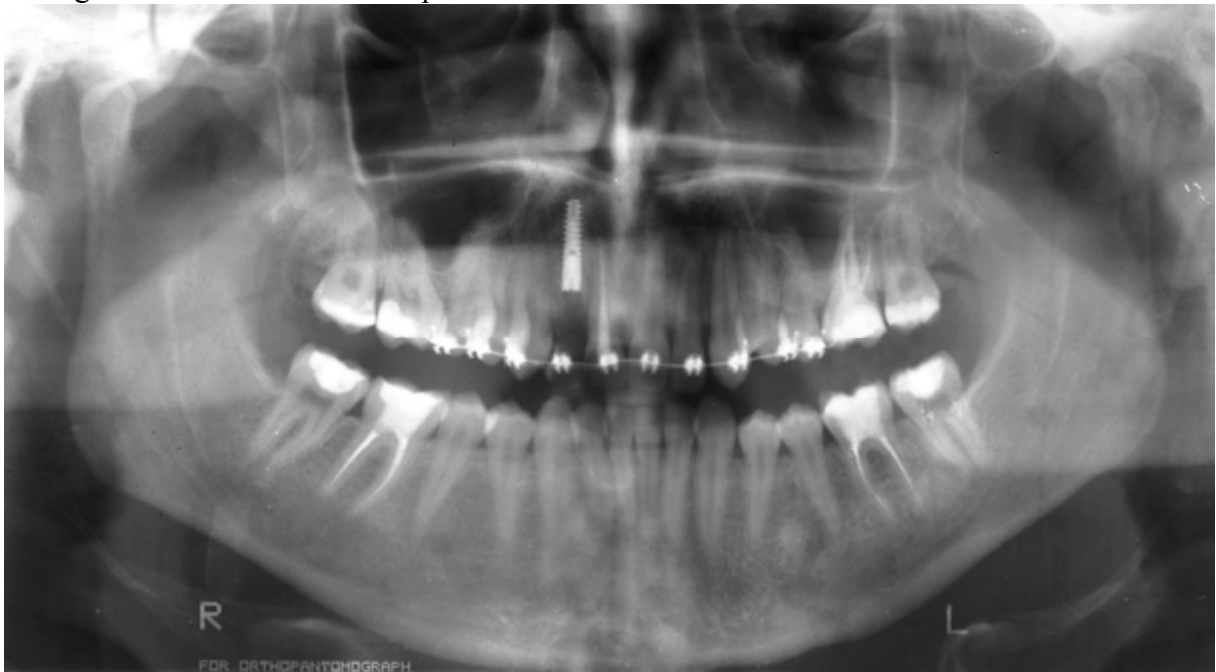

Local rtg 03.09.2007



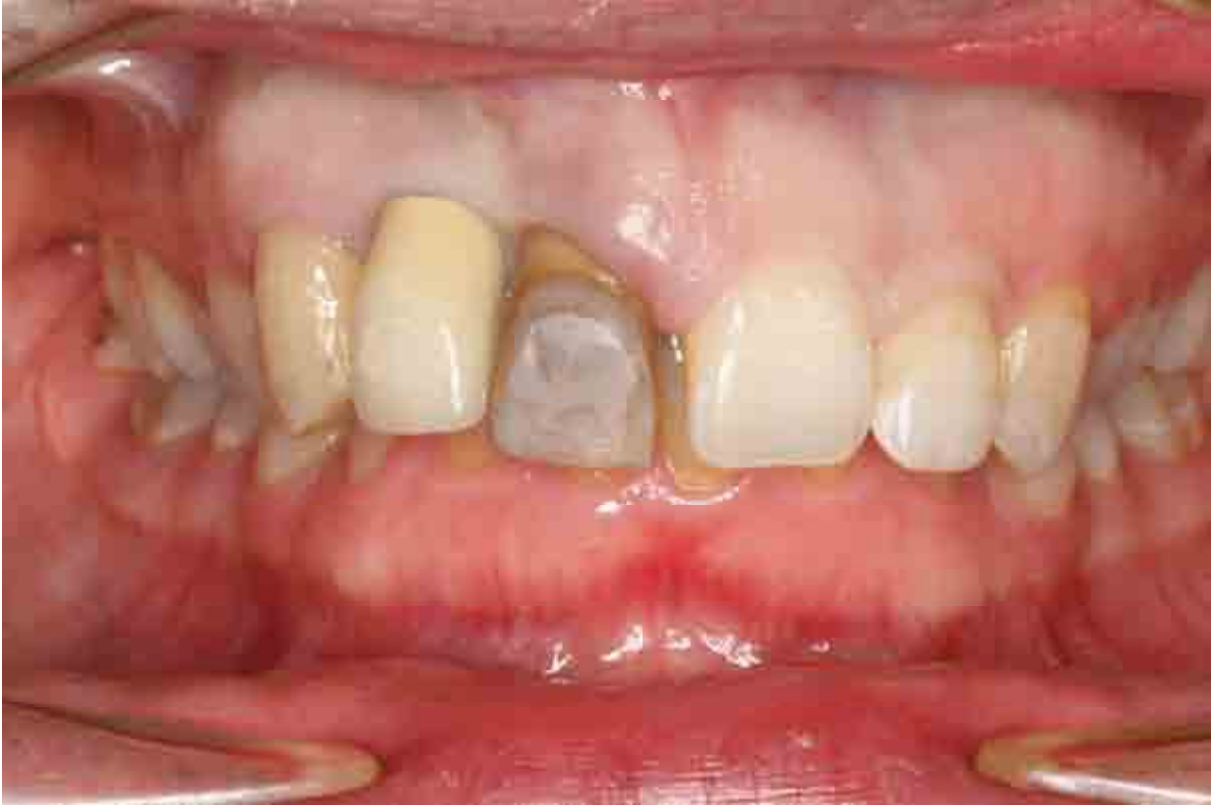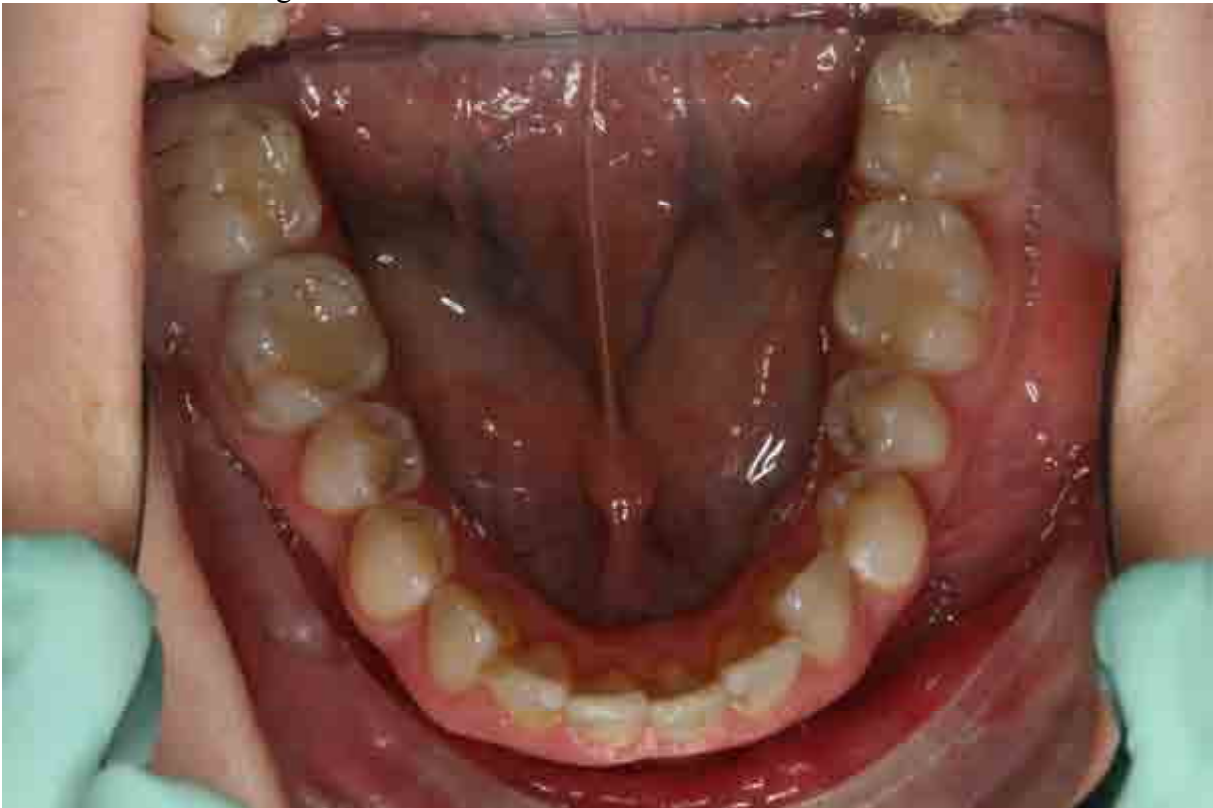Panoramic radiograph after extraction 12 10.12.2007

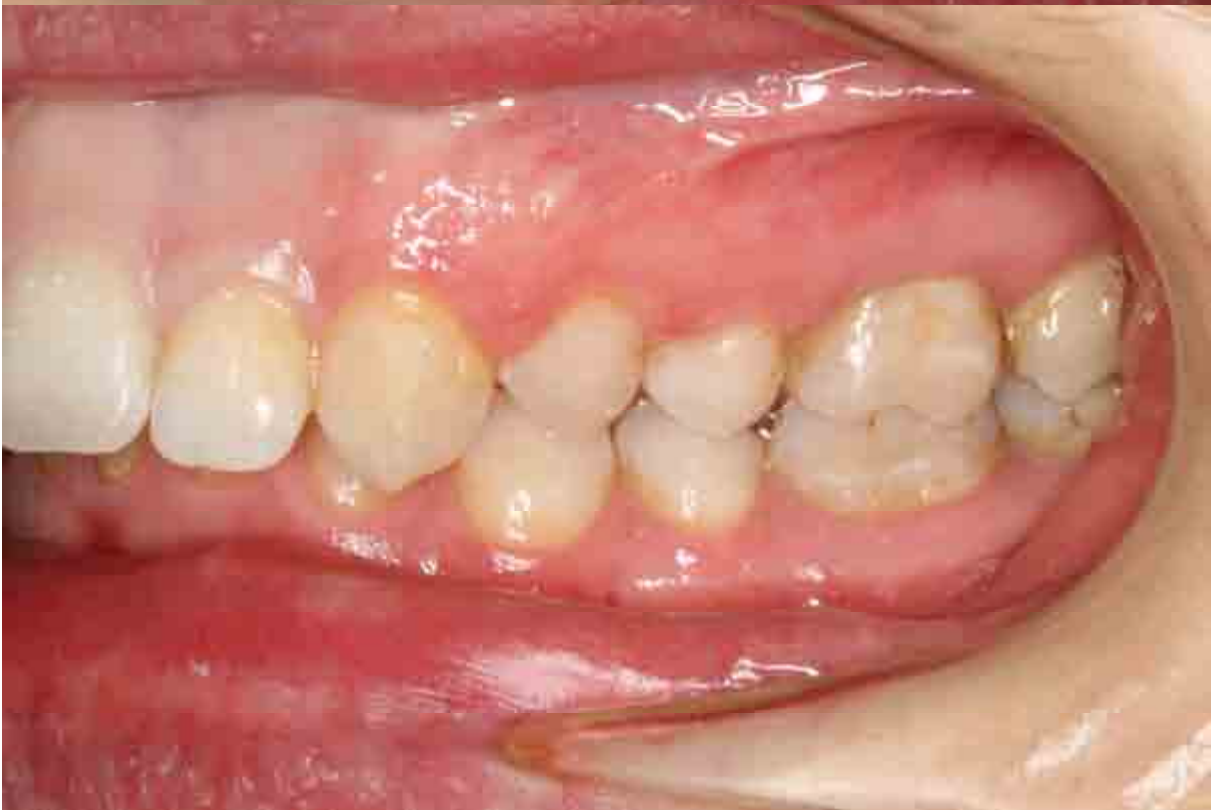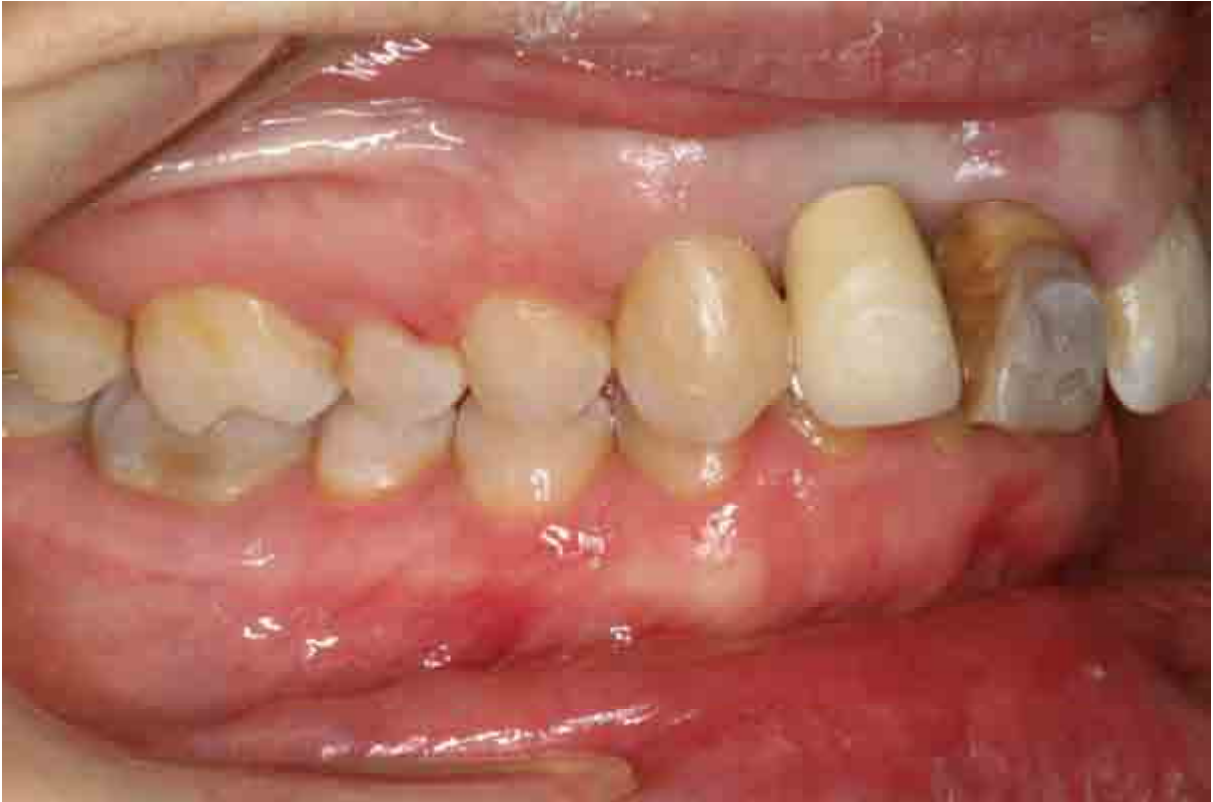In the case of tooth 11 yes. But 12 was broken and I had to take it out, fill the wound with bone graft and later insert the implant.

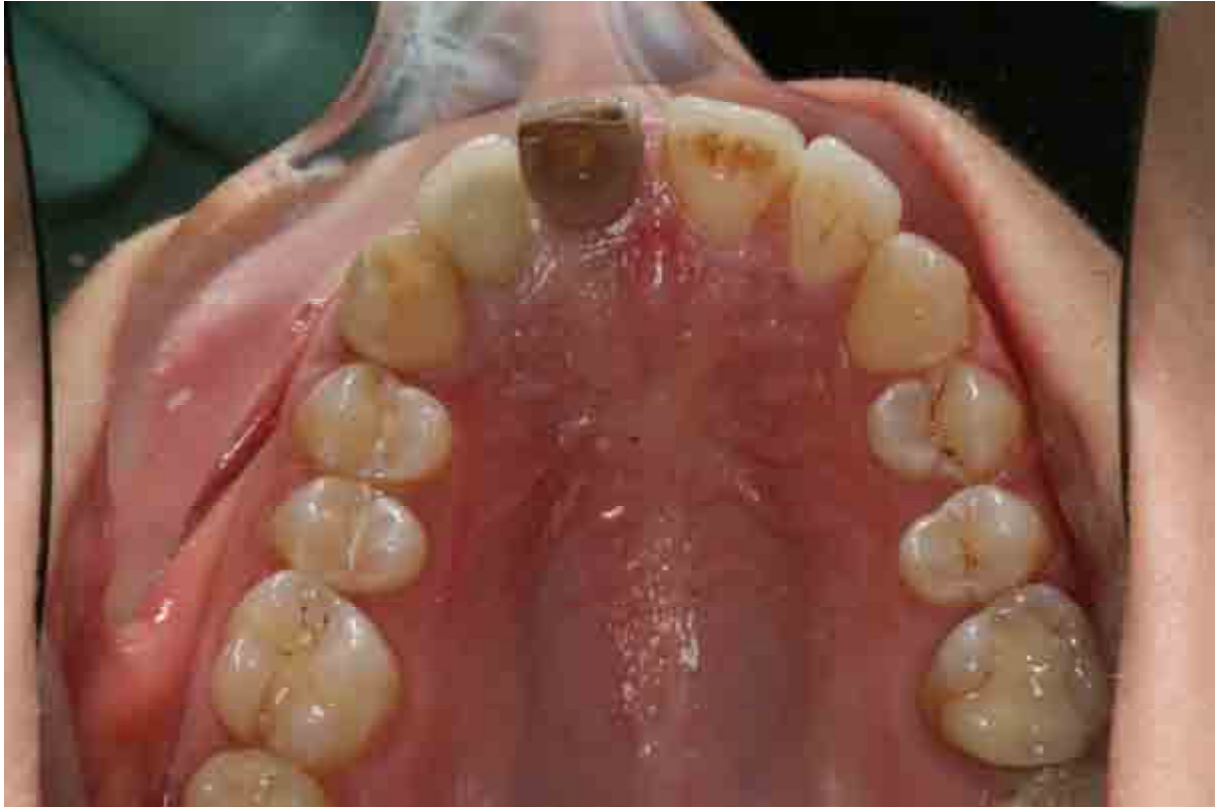

Panoramic radiograph with implant 30.08.2008

Pictures after first stage of orthodontics treatment



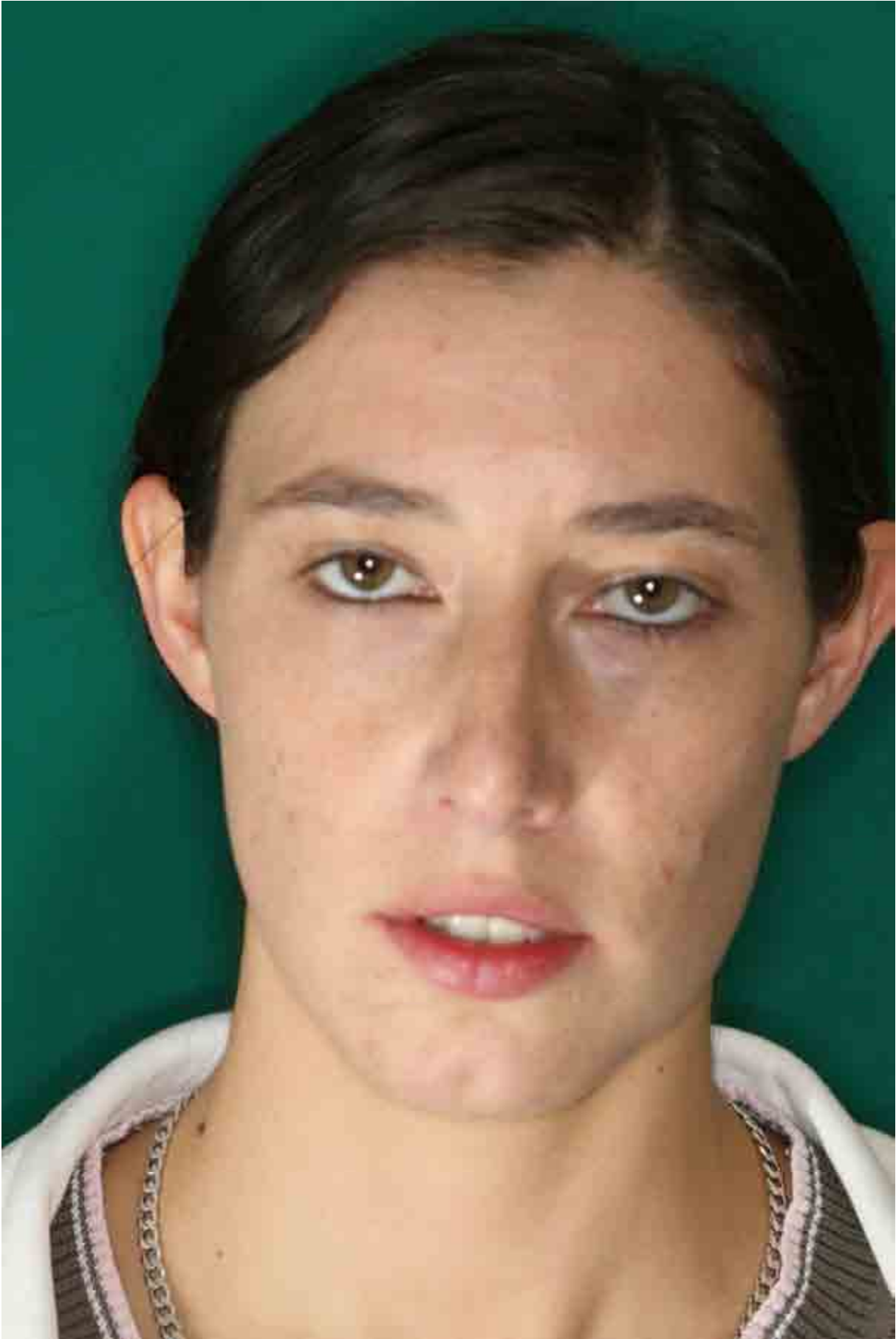



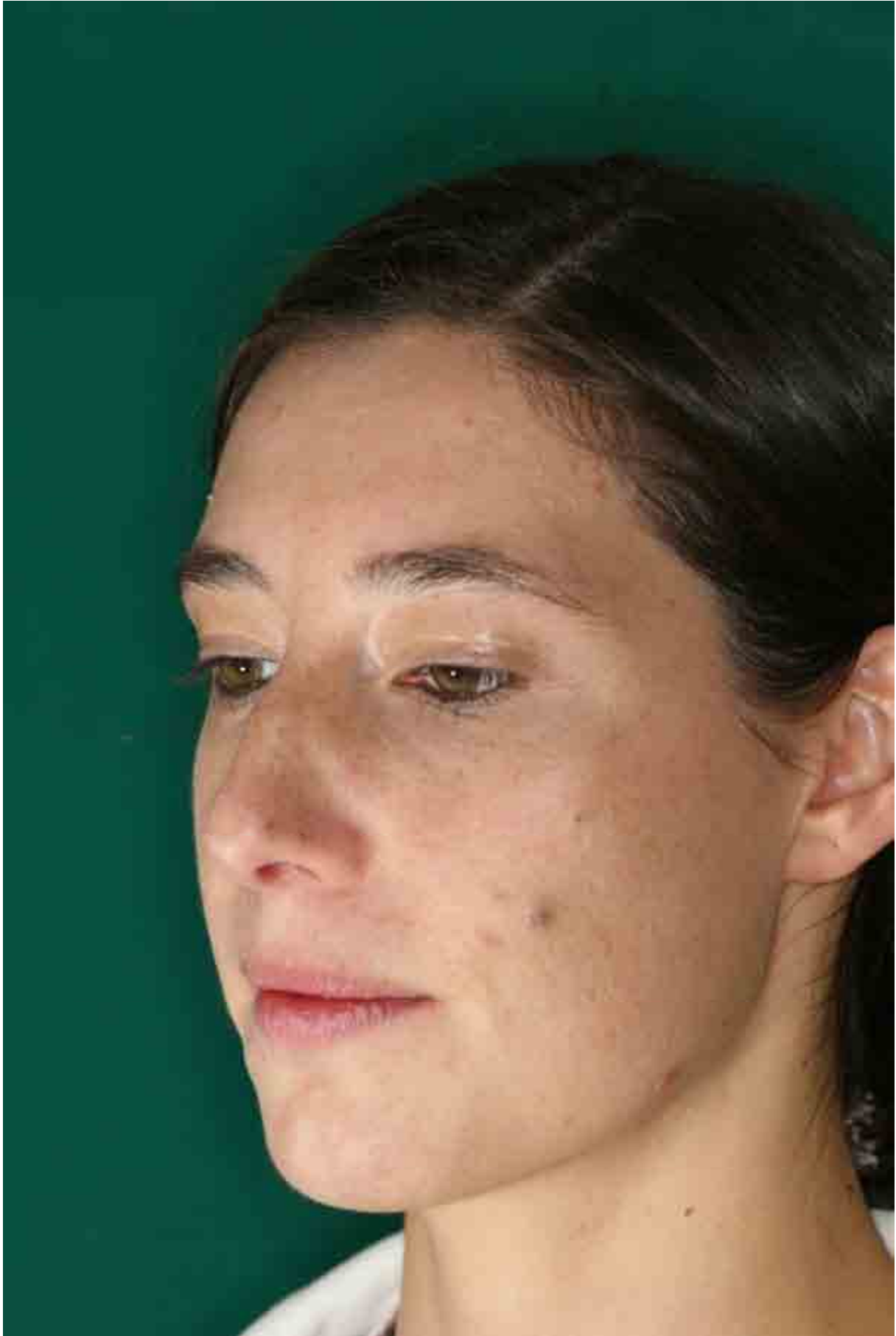
In the second orthodontics treatment, I did some orthodontic gingival trimming and finished with two full porcelain crown restorations on teeth 12,11.

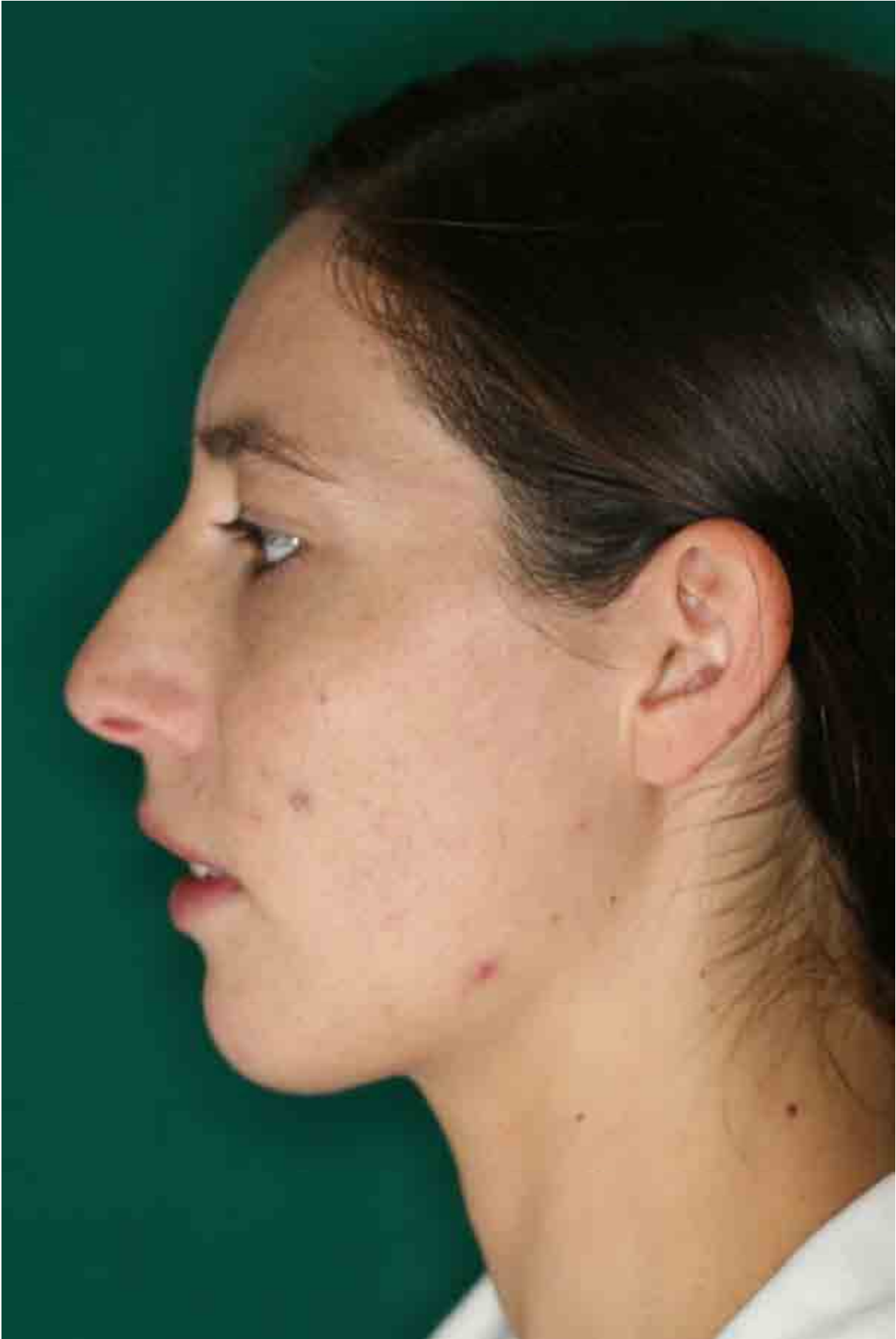She was finished on 17 June 2009.

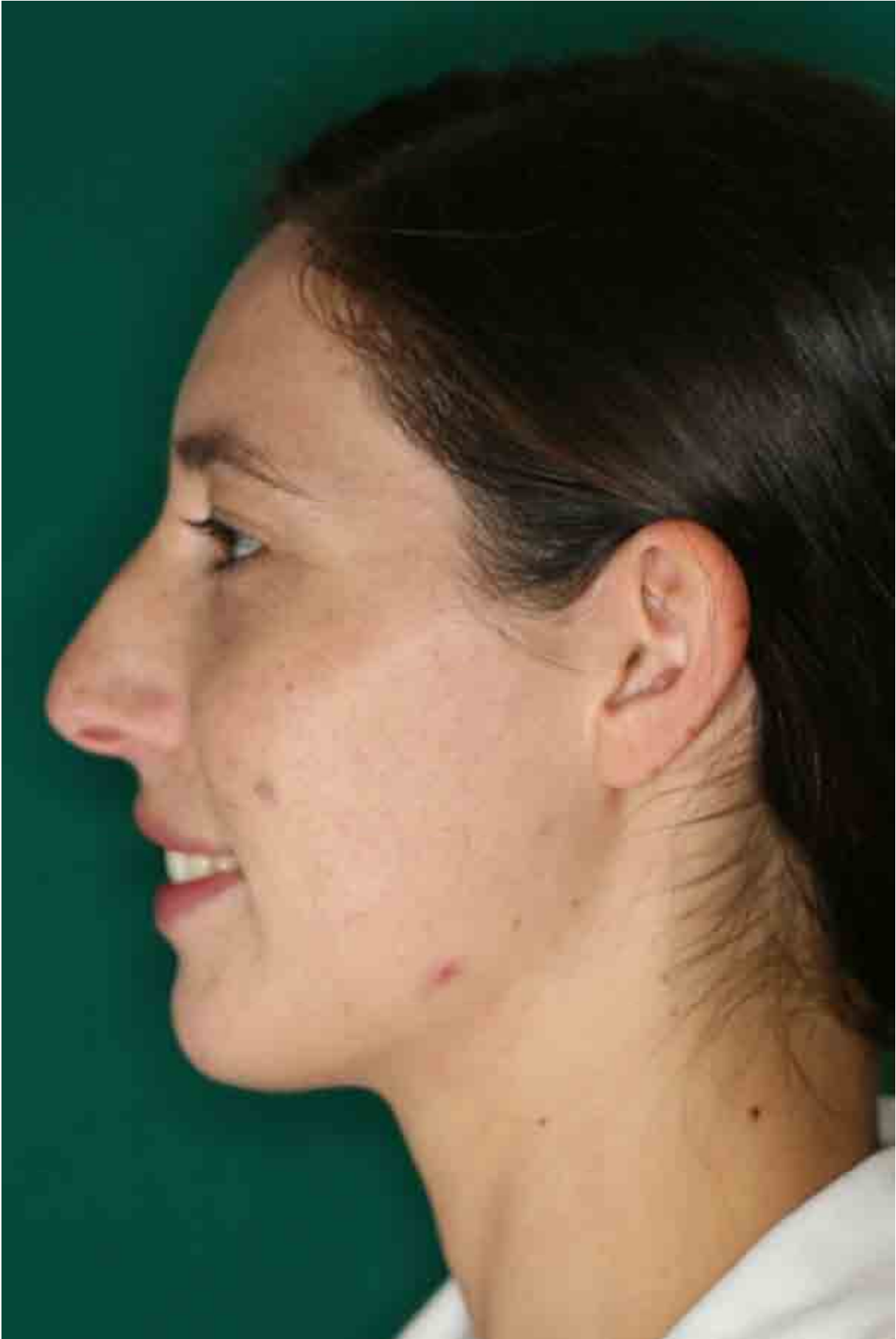


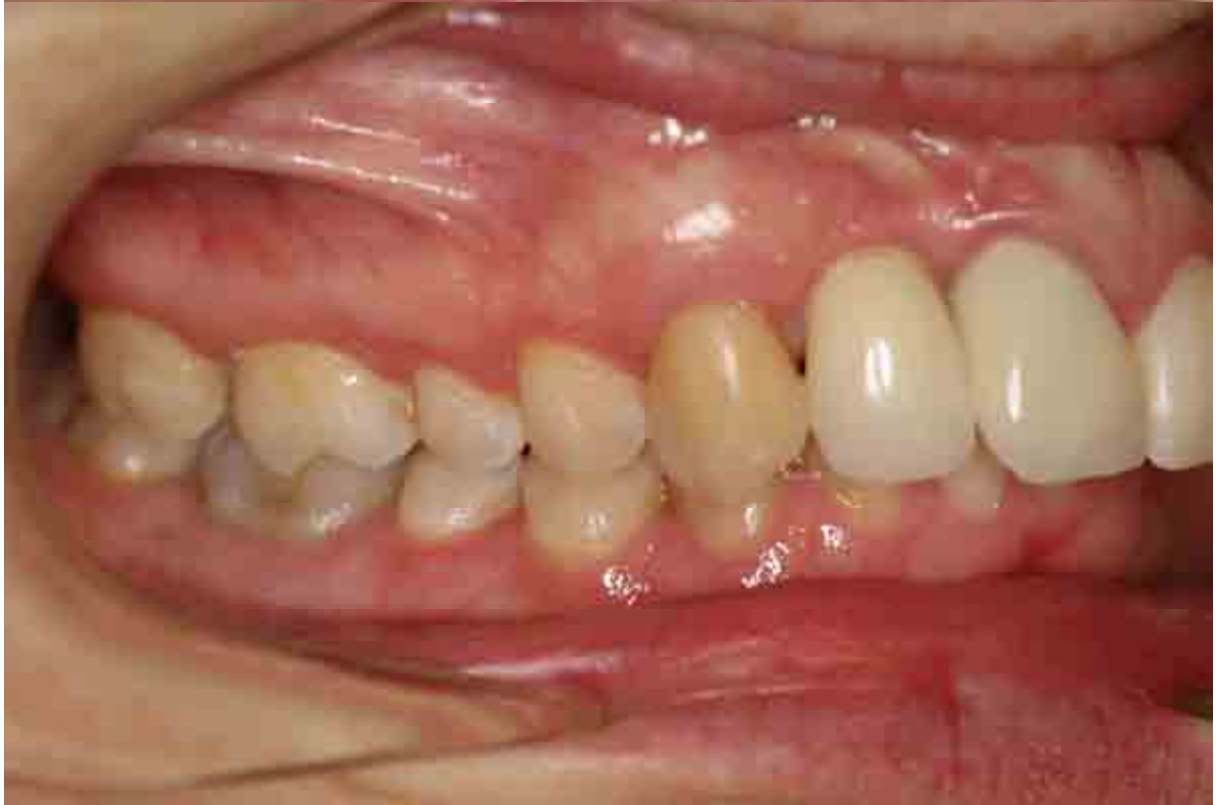
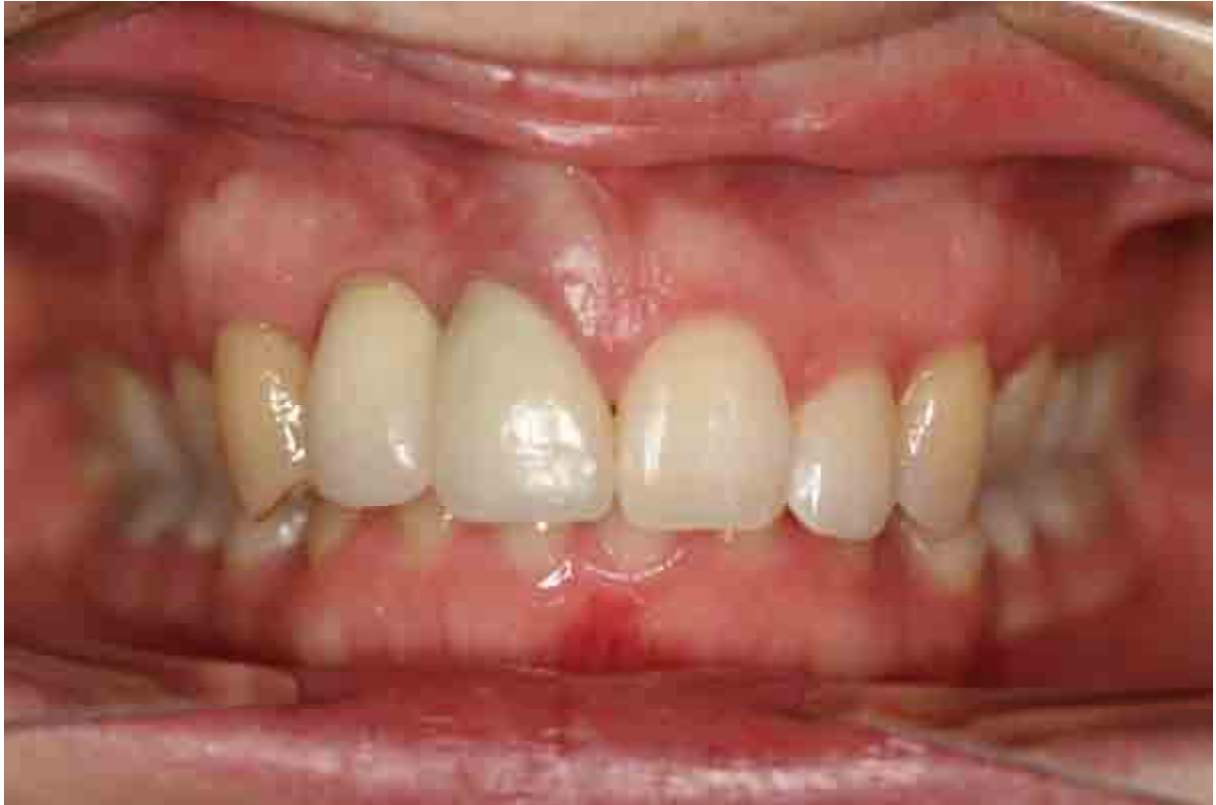


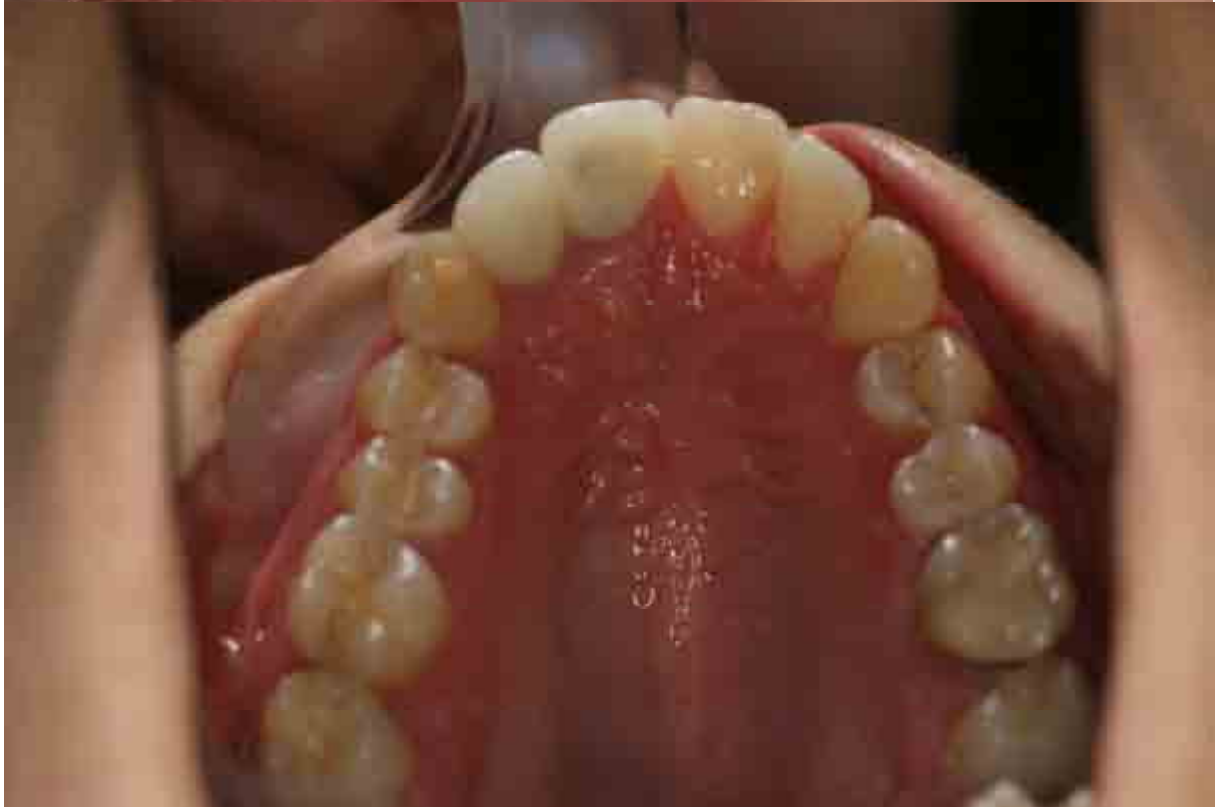
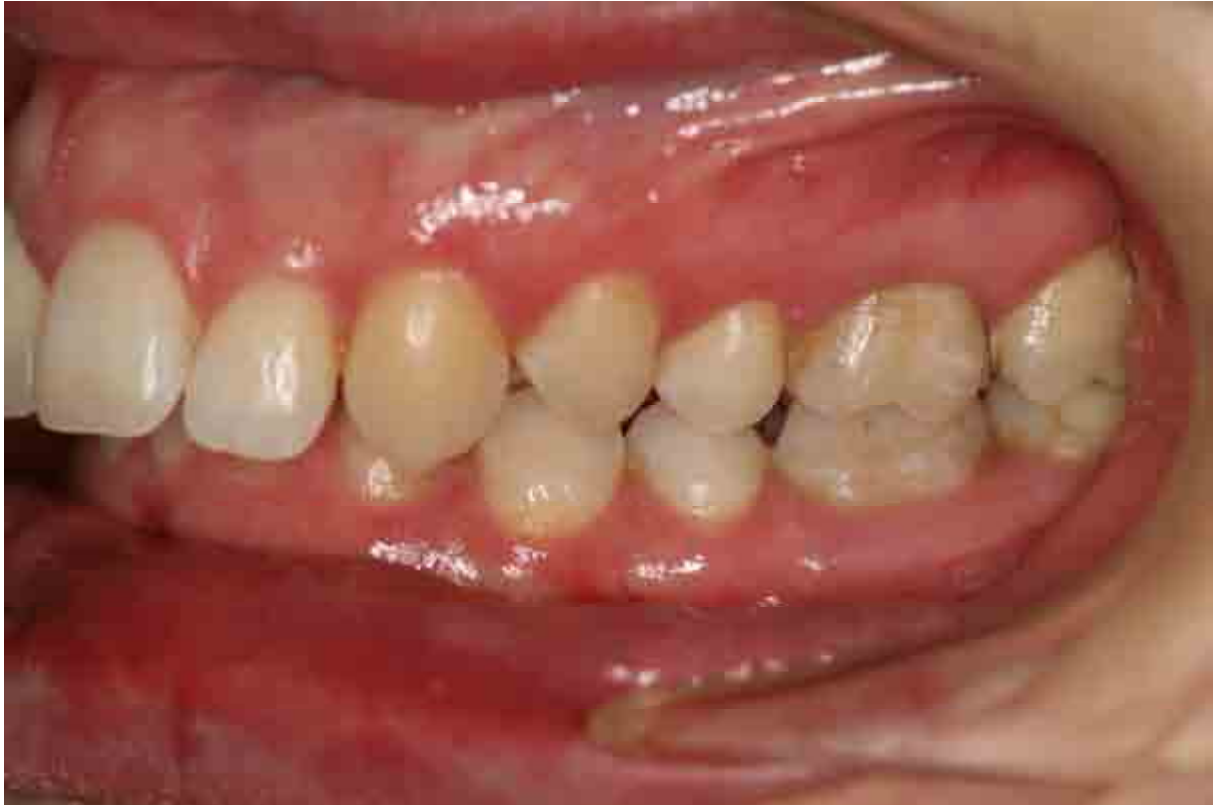


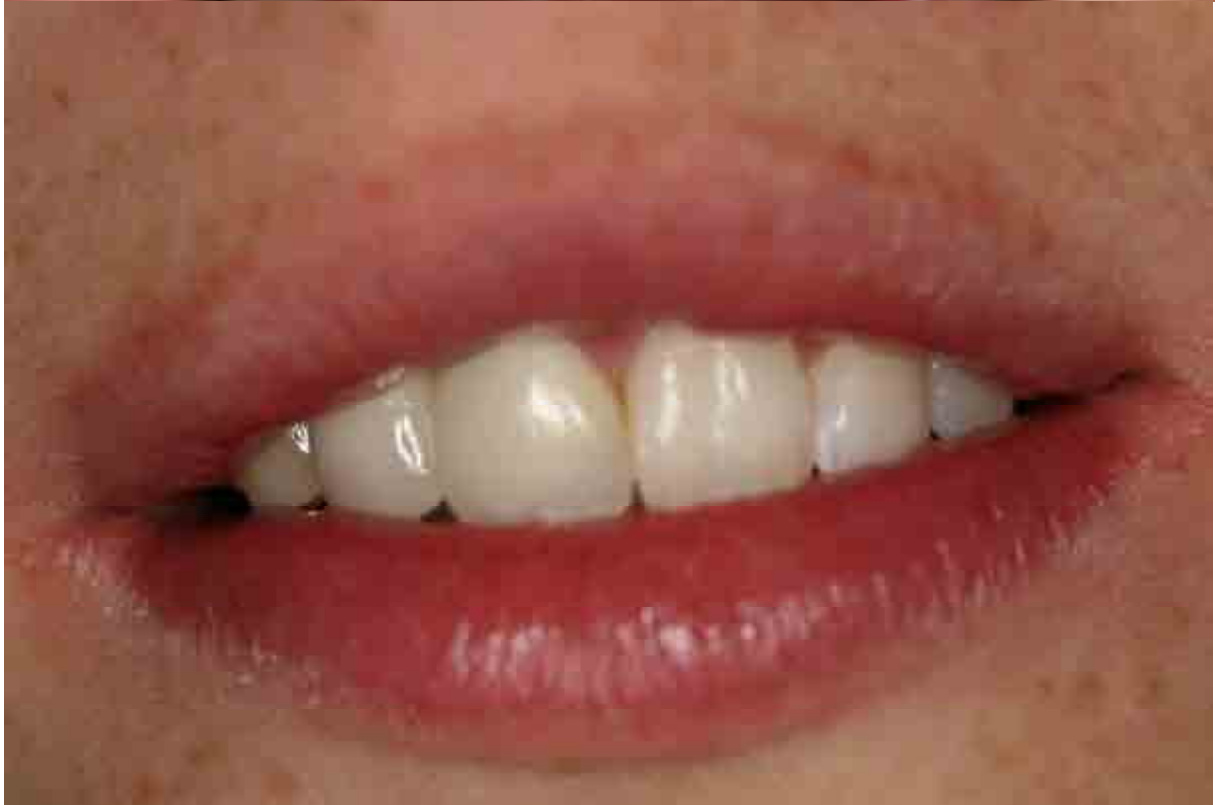
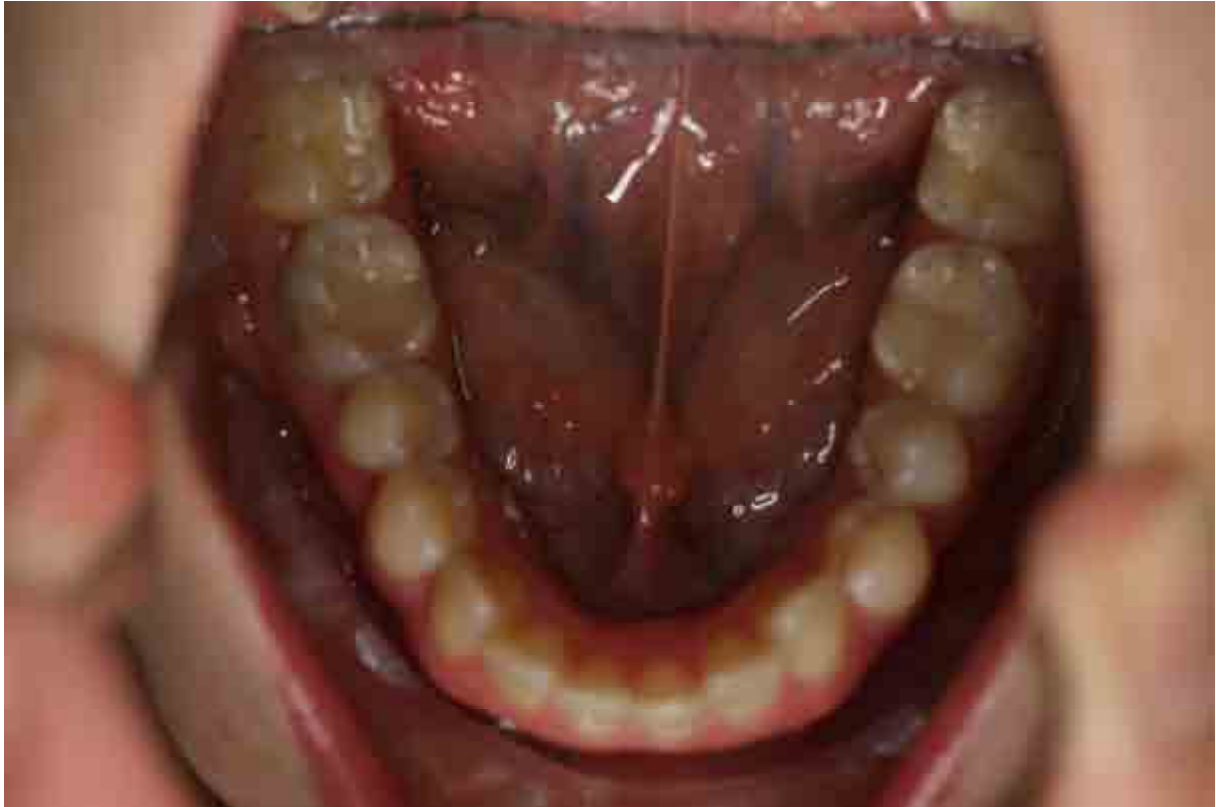


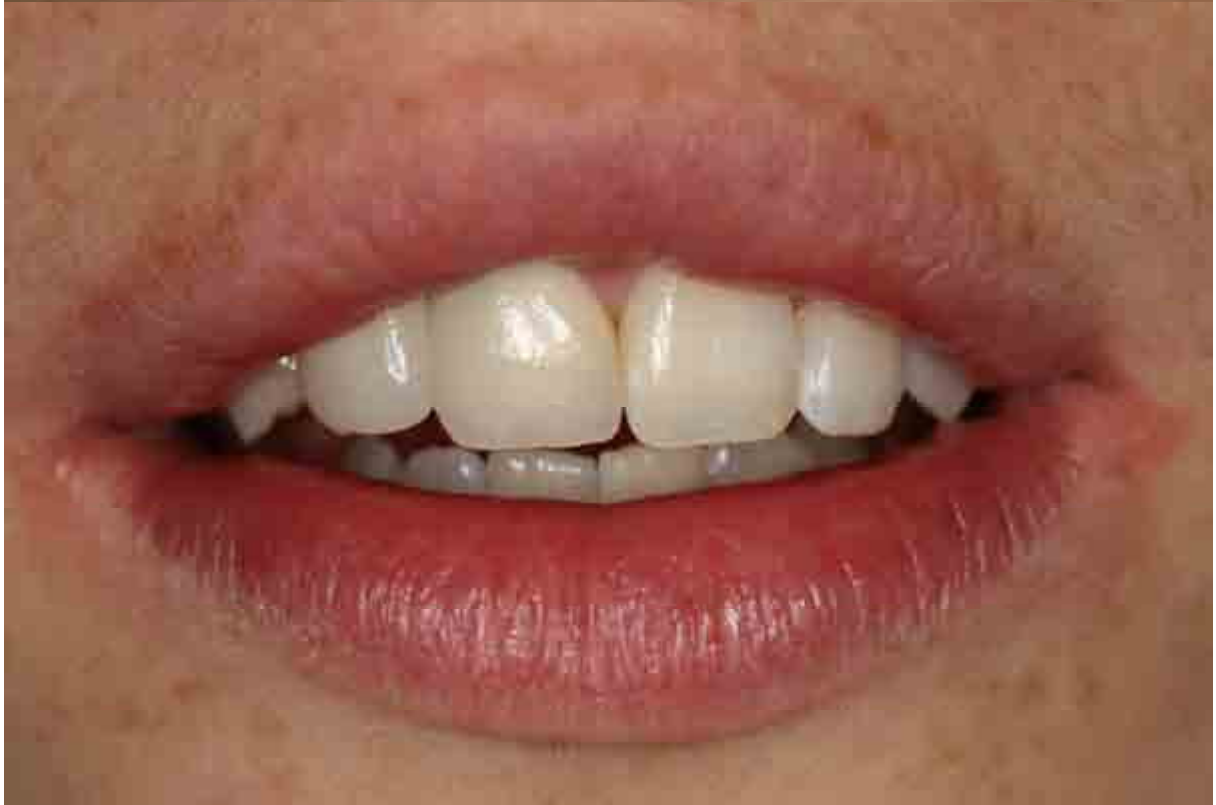
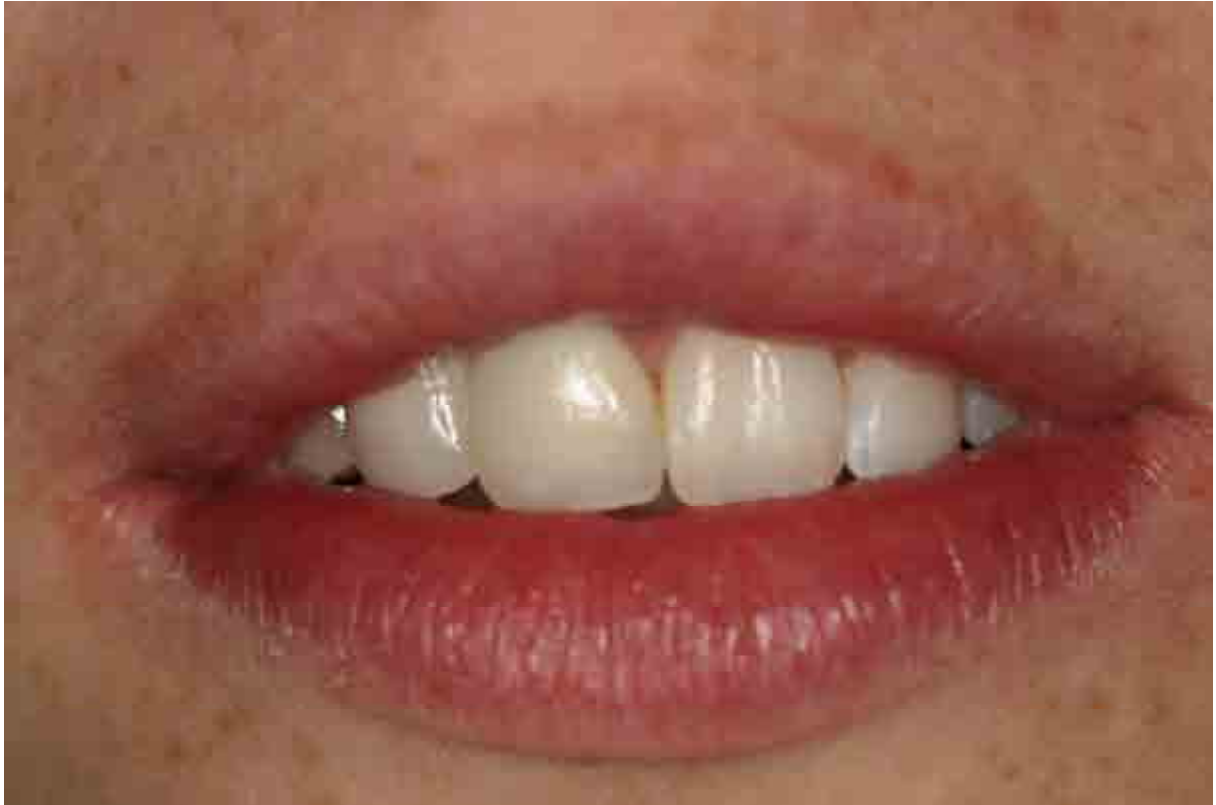


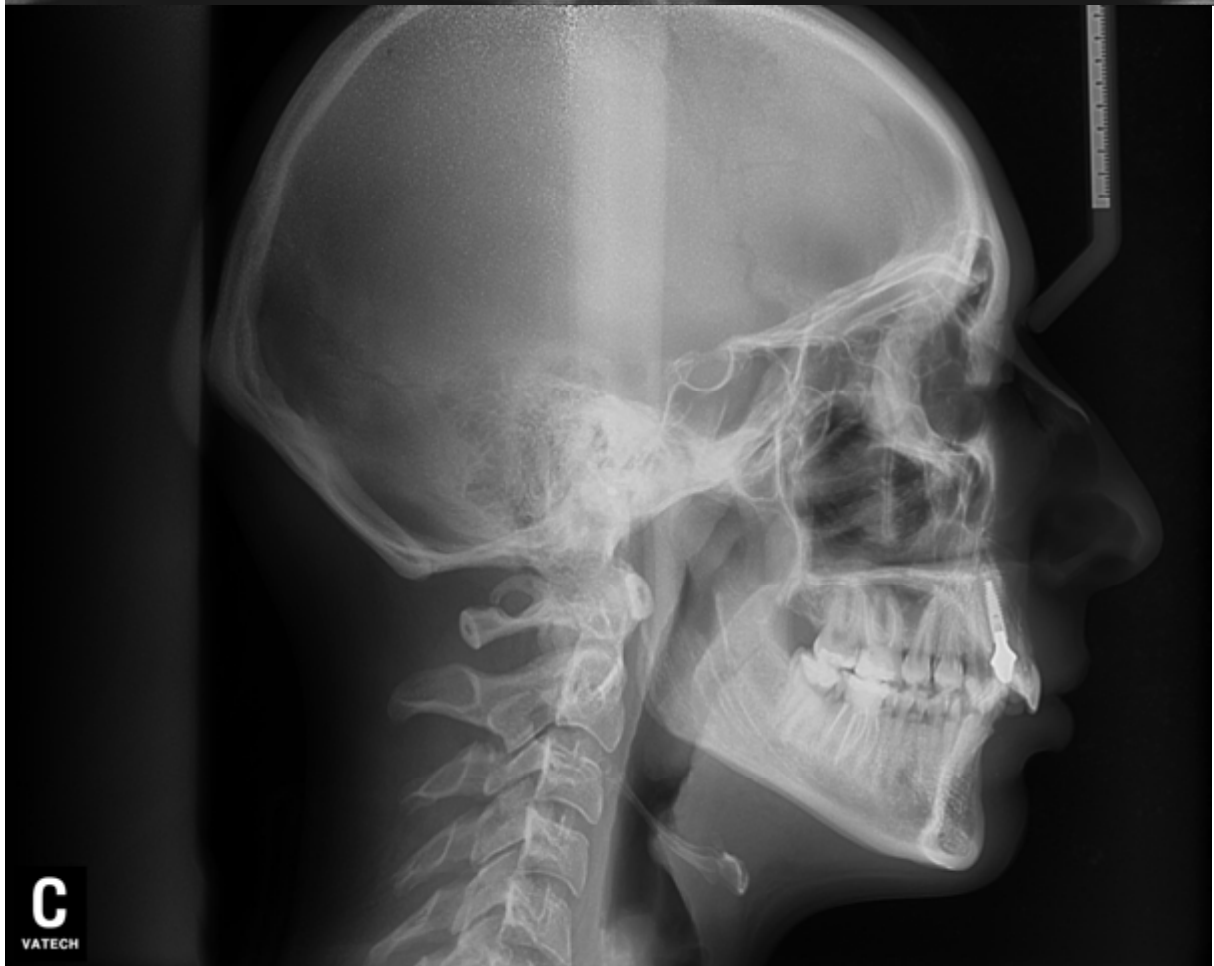
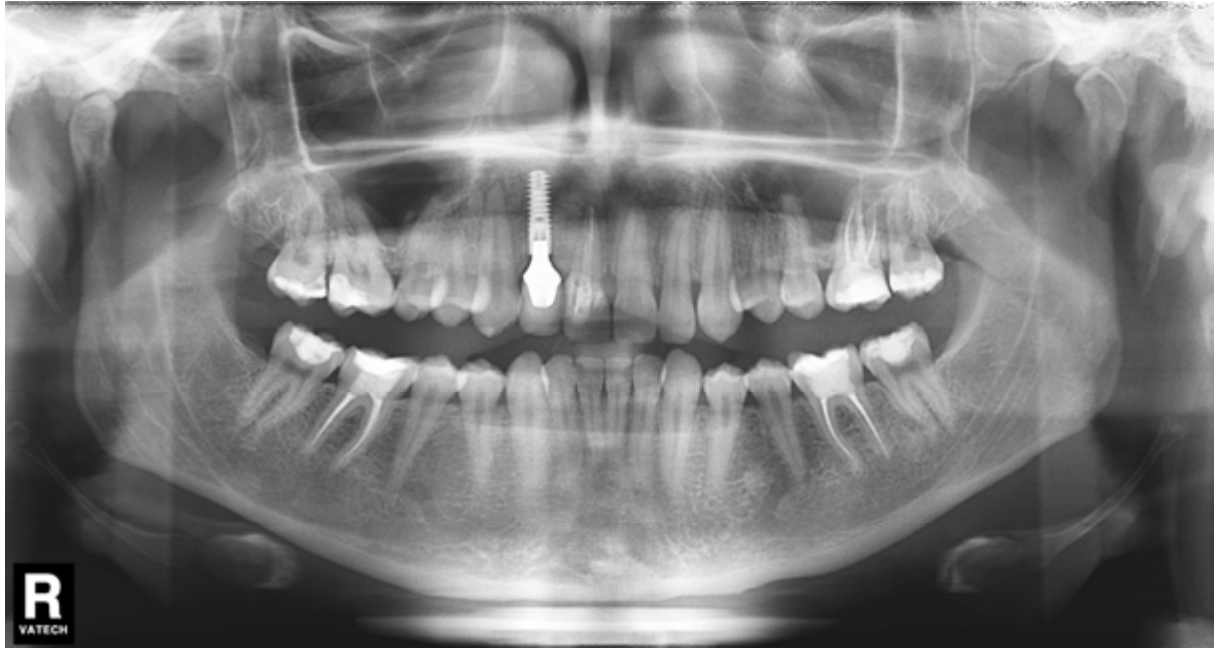

What do you think about this possibility, not reposition of a tooth but orthodontically pull a tooth on the right place? Do you have any suggestions about literature? I would really appreciate your comment.

Best regards

